

A Ait Errami\*, Y El gamrani and K Krati

Department of Gastroenterology and Hepatology,  
Chu Mohammed VI, Marrakech, Morocco

**Dates:** Received: 09 May, 2016; Accepted: 30 May, 2016; Published: 02 June, 2016

\*Corresponding author: Adil Ait Errami,  
Department of Gastroenterology and Hepatology,  
Chu Mohammed VI, Marrakech, Morocco, Tel:  
0021267724909; E-mail: adil.ae@hotmail.fr

[www.peertechz.com](http://www.peertechz.com)

ISSN: 2455-2283

**Keywords:** Bezoar; Trichobezoar; Stomach; Upper endoscopy; Surgery

## Case Report

# Giant Gastric Trichobezoar: Report of Two Cases

### Abstract

We report two cases of gastric trichobezoar, recorded in the last 3 years in our Hospital. Both cases presented abdominal pain and epigastric mass, as well as upper obstructive symptoms. The cases were surgically treated with satisfactory evolution. The clinician has to consider this diagnosis. Surgery is a successful treatment for these cases.

## Introduction

The word “bezoar” corresponds to accumulation of undigestible foreign substances along the digestive tract, most commonly found in the stomach and proximal portions of the small bowel. Bezoars may present different compositions, although classically the most frequently found forms correspond to trichobezoars (agglomeration of hair) and phytobezoars (agglomeration of vegetable fibers) [1,2].

We report two cases of gastric trichobezoar through which will be discussed the diagnostic and therapeutic difficulties.

### Case 1

24-year-old patient J.M consults for chronic epigastric pain associated with postprandial early feeding vomiting, evolving since 2 years in a significant weight loss and anorexia context. In its history we noted a notion of trichophagia since the age of 18.

Clinical examination revealed a body mass index at 14 k/m<sup>2</sup>, discolored conjunctiva, and abdominal examination epigastric mass sensitive to the touch, hard, moving to 2 superficial and deep planes at 20 cm / 10 cm. The remainder of the physical examination was unremarkable.

The blood count showed anemia hypochromic microcytic to 7.1 g / dl. Abdominal CT scan objectified the intragastric presence of a huge mass heterogeneous hypodense, containing bubble area, following the shape of the stomach, which is not enhanced by the injection of contrast material and measures 17 8 cm / 5.78 cm, with discrete thickening of the stomach wall (Figure 1).

Gastroscopy confirmed the diagnosis of trichobezoar showing intraluminal gastric training made of interwoven hair, preventing the progression of gastric and exploration (Figure 2). Given the volume of trichobezoar, endoscopic extraction was impossible. Surgical extraction was performed through a gastrostomy. The postoperative course was uneventful and the patient was sent to a psychiatric consultation to get treated for her eating disorder.

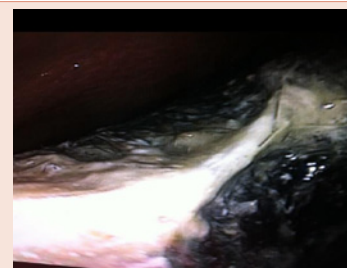
### Case 2

J.K patient aged 18 years with a history of trichophagia and geophagia was seen in gastroenterology consultation for abdominal distension epigastric topography with paroxysmal abdominal pain.

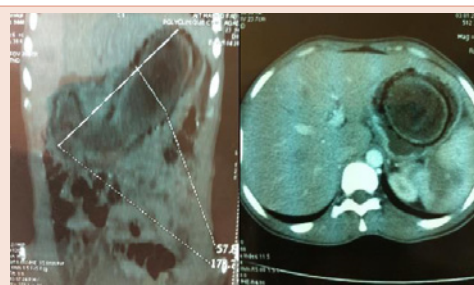
Physical examination revealed in reduced general health, with an anemic syndrome, cachexia with a body mass index of 16 kg / m<sup>2</sup>, the patient presented stable vital signs, with a large (10 × 7.5 cm), hardened and painful epigastric mass at abdominal palpation, with no sign of acute abdomen.

Laboratory tests confirmed the iron deficiency anemia to 6.8 g / dL, with an acceleration of the rate of inflammation e sedimentation to 46 mm first hour and a slight increase in serum fibrinogen.

Abdominal CT scan showed the presence of a huge intragastric heterogeneous mass whose characteristics were suspect a bezoar (Figure 3). Gastroscopy confirmed the diagnosis of trichobezoar (Figure 4), which was surgically removed for its large size. A psychiatric consultation was also recommended.



**Figure 1:** Upper digestive endoscopy. Foreign Typically Corresponding body to a trichobezoar occupying the whole gastric lumen.



**Figure 2:** Abdominal CT shows a large heterogenous intraluminal mass occupying almost the entire stomach.

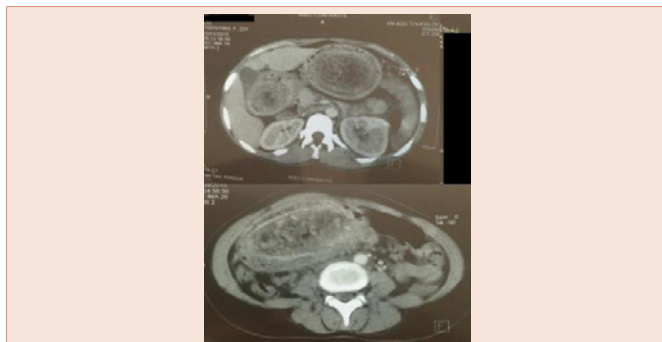
## Discussion

Bezoar corresponds to the unusual accumulation of solid masses in the form of aggregates made of non-digestible substances (hair, plant material, drugs ...) stagnant in the often intragastric digestive tract. The trichobezoar represents 55% of cases. It is an agglomerate of hair or fibers intermingled with each other and associated with food debris serving most often in the gastric lumen [1].

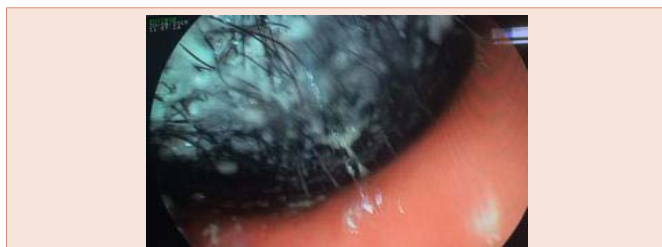
This is a rare condition, which represents 0.15% of gastrointestinal foreign bodies in children [2], and even more rare in adults. Female gender is most affected (90%), and the age of onset is in 80% of cases within 30 years [3].

The trichobezoar is seen most often in patients with a psychiatric history, the mentally retarded and prisoners who have trichophagia [4]. In our patients the trichophagia was present without having noticed a particular psychiatric history where the decision taken subsequent psychiatric care.

The localization of trichobezoar is most often gastric or small bowel [5]. It remains often asymptomatic for a long time of period, discovered incidentally during an assessment of iron deficiency anemia or hypoalbuminemia. Otherwise, it can cause a polymorphic and non-specific symptoms: abdominal pain, vomiting, constipation, poor general condition, foul breath odor [5]. Sometimes a complication in type of acute intestinal obstruction, perforation or gastrointestinal bleeding may indicate [6].



**Figure 3:** Axial computed tomography image at the level of the gastric body demonstrating a mass with “entangled appearance” occupying the whole lumen.



**Figure 4:** Upper digestive endoscopy. Foreign body typically corresponding to a trichobezoar occupying the whole gastric lumen and hindering endoscopic access.

Upper gastrointestinal endoscopy is the examination of choice for the diagnosis of bezoar. The hairball takes the form of an intraluminal mass, made of tangled hair with food debris.

On the abdominal CT scan, the trichobezoar is as a heterogeneous mass, intraluminal. Two pathognomonic signs are constant: the presence of air bubbles in the mass and the absence of any attachment to the gastric wall [7]. This examination like any imaging is not necessary to confirm the diagnosis, it has the role to eliminate organic lesion or exclude any secondary complications.

Therapeutically, endoscopic extraction can be attempted if trichobezoar small or after mechanical fragmentation using a biopsy forceps or a polypectomy loop for the larger size. Excisional surgery at a gastrostomy is indicated for large conglomerates or in case of failure of endoscopic extraction [8]. The presence of a complication (perforation, haemorrhage) always requires surgical treatment [9]. Finally, a psychological treatment of these patients is essential to prevent recurrence [2].

## Conclusion

The positive diagnosis of trichobezoar is endoscopic. Therapeutic management depends on the size of bezoar and the existence or absence of complications. It is often based on surgical removal via the psychological character of patients presenting late. Psychiatric care is essential despite its difficult acceptance in our context.

## Informed Consent

Informed consent for publication of this case was signed.

## Acknowledgement

Dr. Youness El gamrani, for his contribution to the pathology photographs and analysis.

## References

- Chellat H, Amrani L, Hraa A, Amrani N (2011) Trichobézoard gastrique: à propos d'un cas. *Acta Endosc* 41: 8-10.
- Hafsa C, Golli M, Mekki M, Kriaa S, Belguith M, Nouri A, et al. (2005) Trichobézoard géant chez l'enfant. Place de l'échographie et du transit oesogastroduodéal. *J Pédiatr Puer* 18: 28–32.
- Ousadden A, Mazaz K, Mellouki I, Taleb KA (2004) Le trichobézoard gastrique: une observation. *Ann Chir* 129: 237–240.
- Roche C, Guye E, Coinde E, Galambrun C, Glastra C, Halabi M, et al. (2005) Trichobézoard: à propos de 5 observations. *Arch Pédiatr* 12: 1608–1612.
- Zhang RL, Yang ZL, Fan BG (2008) Huge gastric disopyrobezoar: a case report and review of literatures. *World J Gastroenterol* 14: 152–154.
- Kisra K, Kaddouri M, Ablelhak M, et al. (1998) Trichobézoard. *Maroc Med* 20: 255-258.
- El Atmani H, Ibnalah O, Kabbaj N, et al. (2003) Trichobézoard gastrique: a propos d'un cas. *Acta Endoscopica* 33: 569–572.
- Gorter RR, Kneepkens CMF, Mattens ECJL, Aronson DC, Heij HA (2010) Management of trichobezoar: case report and literature review, *Pediatric Surgery International* 26: 457-463.
- Palanivelu C, Rangarajan M, Senthilkumar R, Madankumar MV (2007) Trichobezoars in the stomach and ileum and their laparoscopy-assisted removal: a bizarre case. *Singapore Med J* 48: 37–39.

**Copyright:** © 2016 Errami AA, et al. This is an open-access article distributed under the terms of the Creative Commons Attribution License, which permits unrestricted use, distribution, and reproduction in any medium, provided the original author and source are credited.