

Jastrzębska K\*, Gozdowska J,  
Perkowska-Ptasińska A and Durlik M

Department of Transplantation Medicine,  
Nephrology and Internal Diseases, Medical  
University of Warsaw, Warsaw, Poland

**Dates:** Received: 20 June, 2016; Accepted: 18  
August, 2016; Published: 22 August, 2016

\*Corresponding author: Katarzyna Jastrzębska,  
Department of Transplantation Medicine,  
Nephrology and Internal Diseases, Medical  
University of Warsaw, 02-006 Warsaw,  
Nowogrodzka 59, Poland; Tel; +48 22 502 1035;  
E-mail: jastrz.katarzyna@gmail.com

[www.peertechz.com](http://www.peertechz.com)

**Keywords:** Lupus nephritis; Rapidly progressive  
glomerulonephritis; Crescentic glomerulonephritis

## Case Report

# Rapidly Progressive Glomerulonephritis Associated with Systemic Lupus Erythematosus

### Abstract

Lupus nephritis is a frequent manifestation of multisystem autoimmune disease - Systemic Lupus Erythematosus and a significant cause of both acute renal injury and the end stage renal disease. Renal involvement is observed in approximately 60% of patients with SLE.

We report a case of crescentic glomerulonephritis in a previously healthy 21-year old man who showed signs of insidious symptoms (lower limbs and facial mild edema) in February 2011 and within a brief period developed such clinical features as fever, nausea, vomiting, headache, loin pain, hematuria, oliguria and hypertension. Rapidly worsening renal function became an important determinant of renal failure therefore hemodialysis therapy was introduced. Conducted immunological tests showed an elevated level of antinuclear antibodies and antibodies to dsDNA as well as low complement (C3, C4) levels. The diagnosis of rapidly progressive glomerulonephritis in the background of diffuse glomerulonephritis with crescent formation was confirmed by the presence of pathological features in a renal biopsy. In addition to hemodialysis, treatment with steroids (methylprednisolone) and immunosuppressive agents (cyclophosphamide) was applied.

The therapy resulted in slow but successful clinical improvement. After two months of treatment there was a recovery of renal function and the patient became dialysis independent. Maintenance therapy has been continued for about 4 years. The serum creatinine level is about 1.2 mg/dL, without proteinuria.

Crescentic glomerulonephritis in the course of SLE correlated with unfavorable prognosis and therefore must be treated promptly to prevent irreversible kidney injury. This case illustrates the potential of long-term high-dose immunotherapy in the treatment of RPGN in the course of SLE.

## Abbreviations

SLE: Systemic Lupus Erythematosus; ANA: Antinuclear Antibodies; dsDNA: Double Stranded/Native DNA; RPGN: Rapidly Progressive Glomerulonephritis; ISN: International Society Of Nephrology; RPS: Renal Pathology Society; DPGN: Diffuse Proliferative Glomerulonephritis; GN: Glomerulonephritis; GFR: Glomerular Filtration Rate; RBC: Red Blood Cells; HTC: Hematocrit; ANCA: Anti-Neutrophil Cytoplasmic Antibodies; AFOG: Acid Fuchsin Orange G; PAS: Periodic Acid-Schiff; Gcs: Glucocorticoid; MMF: Mycophenolate Mofetil; KIDIGO: Kidney Disease: Improving Global Outcomes; CKD: Chronic Kidney Disease; ESDR: End Stage Renal Disease; CYC: Cyclophosphamide; LN: Lupus Nephritis; AZA: Azathioprine; ACE: Angiotensin-Converting Enzyme; AVN: Avascular Necrosis; INF: Interferon; IL: Interleukin; TNF: Tumor Necrosis Factor;

## Introduction

Systemic Lupus Erythematosus (SLE) is a multisystem autoimmune-related disease of unknown origin with the presence of circulating antibodies against a variety of cellular antigens [1].

Clinically, SLE may be presented as multi-organ lesions or the involvement of only one system organ accompanied or preceded by additional symptoms in the course of the illness [2]. SLE is more

common among women (female-to-male ratio of 9:1) aged 20-40 years. Lupus nephritis is a frequent manifestation of SLE among adult patients. According to current research, approximately sixty per cent of lupus patients will evolve clinically significant kidney damage [3]. The inflammation may involve all components of renal parenchyma, however, glomerular abnormality is a reliable prognostic indicator in lupus nephritis [4]. The clinical expression of lupus nephritis is highly changeable, varying from asymptomatic proteinuria to kidney insufficiency.

The prevailing classification (revised by the International Society of Nephrology - ISN and the Renal Pathology Society - RPS in 2003) based on pathology proved in renal biopsy, has divided the varied forms of renal injury in SLE nephritis into six histological categories [4]. Diffuse proliferative glomerulonephritis (DPGN) (ISN/RPS class IV) tend to exhibit the worst prognosis [5]. Rapidly progressive glomerulonephritis (RPGN) is a clinical term defined by severe loss of renal function induced by expansion of inflammatory process in glomerulus. A common effect of RPGN is the rapid reduction in the glomerular filtration rate of at least 50% over 3 months and clinical evidence of glomerular injury in the form of active urinary sediment including red blood cell casts. In patients with RPGN, renal biopsy typically demonstrate widespread glomerular crescent formation. Standard nephrological diagnosis is performed using a fluorescence technique which allows to divide glomerular disorders

into three possible patterns: granular positivity consistent with immune complex-mediated GN, linear positivity caused by anti-glomerular basement membrane disease, or no significant positivity, corresponding to "pauci-immune" crescentic GN.

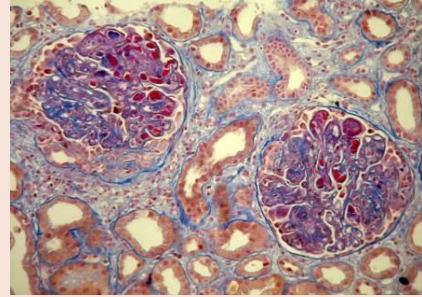
### Case Presentation

A previously healthy 21-year old man was admitted to a provincial hospital with complaints of fever, nausea, vomiting, headache, loin pain, hematuria, oliguria and hypertension. Laboratory tests showed: hemoglobin 9.7 g/dL (hematocrit 29%), platelet count 75 G/L, white blood cell count 4 G/L, C-reactive protein 24.5 mg/dL, blood urea nitrogen levels of 143 mg/dL and serum creatinine concentration of 6 mg/dL, estimated GFR 12 mL/min. In urinalysis, protein of 1210 mg/dL, red blood cell (RBC) 50-70/ high power field, urinary cast. The patient was diagnosed with nephrotic syndrome characterized by high range proteinuria (protein 3630 mg/day), hypoalbuminemia, (serum albumin of 1.7 g/dL), hyperlipidemia (cholesterol 276 mg/dL, triglycerides 366 mg/dL) and edema. Ultrasound scans showed enlarged kidneys (12 cm length) and increased renal parenchyma echogenicity. Within a brief period, renal function had severely deteriorated therefore treatment was initially changed to hemodialysis therapy. Glomerulonephritis was suspected and patient was referred to the Department of Transplantation Medicine and Nephrology.

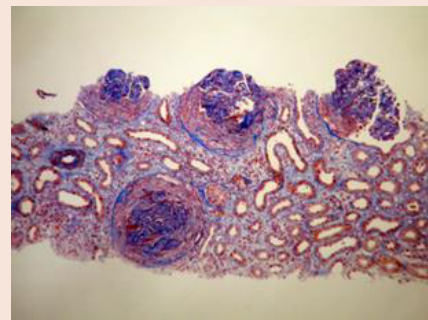
On hospital admission urinalysis showed an active urine sediment: 1200.9 mg/dL protein, hematuria, leukocyturia and urinary cast. Levels of complement components C3 and C4 were reduced (C3 42 mg/dL, C4 3.7 mg/dL). Laboratory test showed decreased hematocrit (HCT 28%) and hemoglobin (Hb 9.4 g/dL). Immunological tests for the detection of antinuclear antibodies and antibodies to double-stranded DNA, were positive and showed an elevated titer of both serum antibodies: ANA 1:10 000; anti-dsDNA 1: 1000. The patient's serum tested negative for anti-neutrophil cytoplasmic antibodies (cANCA, pANCA) and anti-glomerular basement membrane antibodies.

Differential diagnosis to exclude other illnesses such as a renal vein thrombosis, infective endocarditis, hepatitis B, hepatitis C, monoclonal gammopathy, rheumatoid arthritis, antiphospholipid syndrome and cryoglobulinemia was conducted.

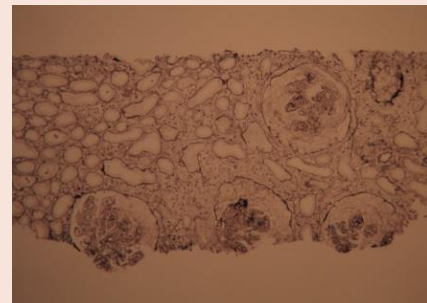The patient underwent an ultrasound monitored biopsy, twenty-nine glomeruli were evaluated. An examination of renal tissue by light microscopy revealed the presence of crescents in more than 82% of glomeruli - seventeen glomeruli, with epithelial crescents, seven with fibroepithelial crescents and the appearance of segmental capillary sclerosis. (Figures 1-6) Immunofluorescence studies showed a moderately diffuse deposition of IgG, C3, C1q along the glomerular capillary and in the mesangium. Proliferating cells accompanied by fibrin deposition and inflammatory cell infiltration were found in renal parenchyma. Therefore, the patient was diagnosed with diffuse glomerulonephritis with epithelial and fibroepithelial crescent formation involved more than 50 % of glomeruli in the biopsy. Immunofluorescence tests and clinical history indicate SLE as a primary cause of acute kidney injury. The presence of Lupus nephritis was certified and classified as an IV G a/c class according to INS/RPS classification.



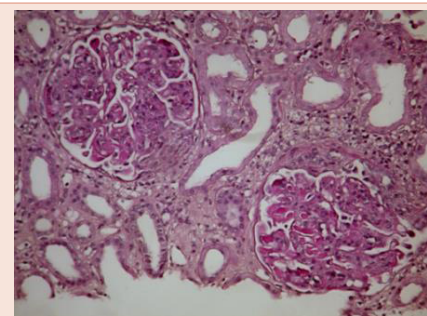
**Figure 1:** AFOG trichrome staining-fibrinoid necrosis, crescent formation, hyaline thrombi in glomerular capillary lumen.



**Figure 2:** AFOG trichrome staining-fibrinoid necrosis, crescent formations, interstitial fibrosis and edema.



**Figure 3:** Jones methamine silver-glomeruli with crescent formation.



**Figure 4:** PAS staining- crescentic glomerular lesions, segmental glomerulosclerosis, diffuse proliferation, hyaline thrombi in glomerular capillary lumen.

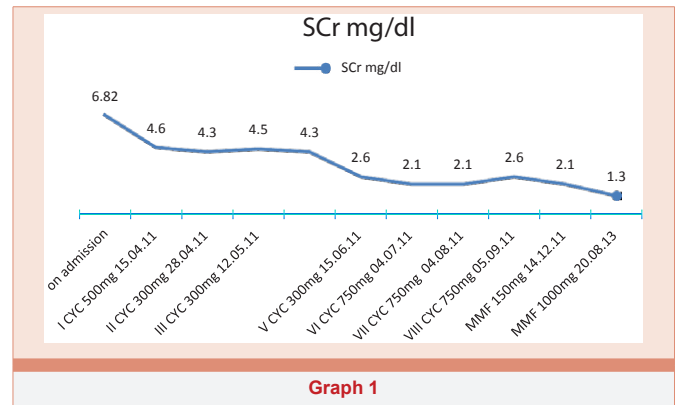
The patient with insidious symptoms, rapidly developed full blown acute kidney injury due to lupus nephritis, therefore, aggressive immunosuppressive treatment was given. Induction therapy with pulses of high-dose glucocorticoid (methylprednisolone 1g) was applied for three days and continued with glucocorticoid (prednisone) at a dosage of 60mg/day orally. Simultaneous with GCs infusions the first cyclophosphamide infusion (500 mg IV) was applied. Intravenous therapy with immunosuppressive agent encompassed eight infusions, therefore in the final analysis, 4450 mg of Cyclophosphamide (60.15 mg/kg body weight) was given.

The therapy resulted in very slow clinical improvement. After two months of treatment the kidney function recovered and the patient became dialysis independent. Immunotherapy was diverted to mycophenolate mofetil (MMF 3x500mg) orally and tapered doses of corticosteroid. Actually the patient receives prednisone 5 mg/day and MMF 1000 mg/day. Renal function has recovered with serum creatinine concentration of 1.2 mg/dL, without proteinuria (Graph 1-3).

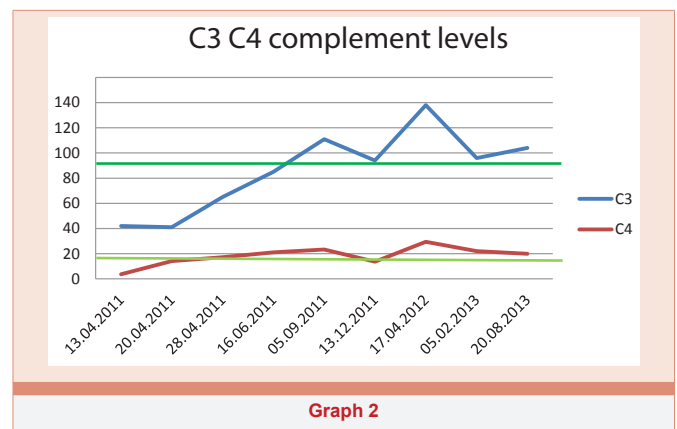
During the 4-year follow-up, serious adverse effect, avascular necrosis of both femoral heads was reported. Osteonecrosis was related to therapy with corticosteroid medication and treated symptomatically.

**Discussion**

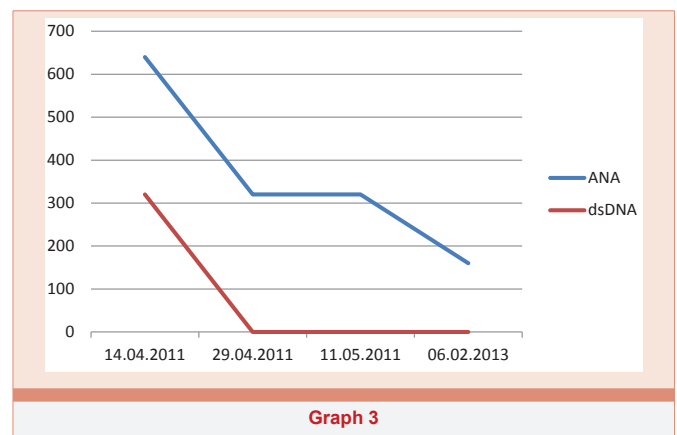
Systemic Lupus Erythematosus is a multisystem autoimmune disease, typically with the presence of dermatologic, rheumatologic, hematologic, and renal involvement. Lupus nephritis is associated



Graph 1



Graph 2



Graph 3

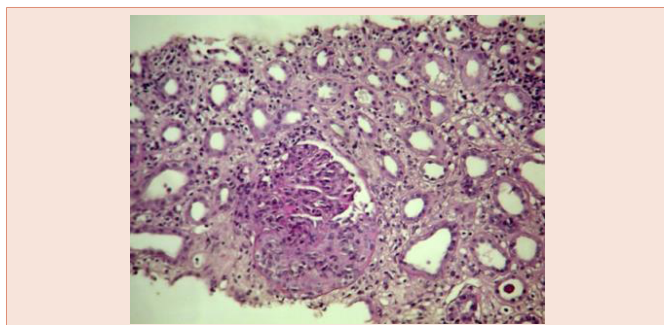


Figure 5: PAS staining-proliferation in vascular tissue(vascular bundle), fibroepithelial crescent, influx of inflammatory cells in the mesangium.

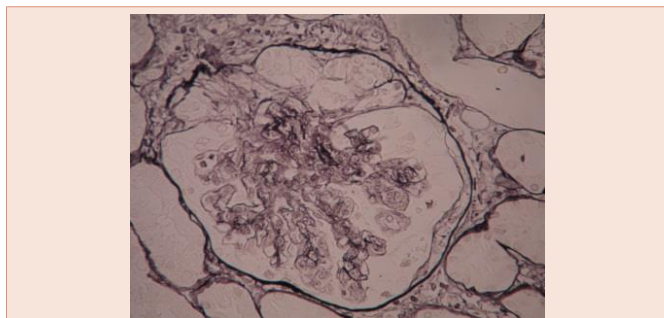


Figure 6: Jones methamine silver-glomeruli with crescent formation.

with significant increase in mortality in patient with SLE [6]. Untreated RPGN particularly, carries a poor prognosis and unavoidable progress to the final stage of renal disease.

Rapid deterioration of renal function among patients with RPGN requires adequate anti-inflammatory therapy which should be adjusted according to the extent of activity and chronicity and provided without delay.

Due to KIDIGO (Kidney Disease: Improving Global Outcomes), guidelines for the management of lupus nephritis standard therapy consists of the induction phase, followed by consolidate treatment. The initial treatment with glucocorticoids (dose of oral prednisone

up to 1mg/kg; i.v. methylprednisolone is extensively prescribed at the beginning of treatment for more severe diseases) combined with, either, cyclophosphamide (0.5-1g/m<sup>2</sup> intravenously; 1-1.5mg/kg/d max dose 150mg/d orally) or mycophenolate mofetil orally (max 3g/d), should be administered to patients with class III and IV to reduce inflammation and control immunological activity in renal tissue. Combination induction treatment with multiple agents showed benefits in controlled trials and decreased the frequency of kidney relapse, CKD and ESDR compared to corticosteroids alone [7]. The main goals of this therapy is to achieve a complete renal remission and recovery of renal function or, at least, to prevent progression of the disease [8].

Our patient received induction therapy with steroid infusion for three days and intravenous CYC and continued when the patient was on hemodialysis. Intravenous therapy with immunosuppressive agent encompassed eight infusions. The examination of renal tissue revealed potentially reversible active changes (epithelial crescents) furthermore, the conducted immunological test showed elevated levels of ANA and anti-dsDNA and low complement components C3 and C4 levels -which convinced us to maintain treatment. After two months of intensive therapy, the kidney function recovered and biochemical parameters had very slowly normalized. The patient became hemodialysis independent. Immunosuppressive therapy with cyclophosphamide was diverted to mycophenolate mofetil and tapered doses of steroids. Adjunct therapy with angiotensin receptor blockers to control blood pressure and reduce proteinuria was given.

All the immunosuppressive regimens used in the therapy of LN have side effects and the toxicity of medication is far from ideal. There are many limitations of current therapies: infections (especially for patients who are on dialysis therapy [8]) including sepsis, thrombosis, infertility (cyclophosphamide) malignancy-bladder (cyclophosphamide), cervical dysplasia, antiphospholipid antibody syndrome, hypercholesterolemia and coronary heart disease, cytopenia (AZA) osteoporosis and avascular necrosis of the bone, or severe myopathy [9,10]. That's why SLE patients with LN need close monitoring, optimizing of drug dosage and may require appropriate prophylaxis in the form of adjunct therapy with: angiotensin-converting enzyme (ACE) inhibitors to control blood pressure and reduce proteinuria, statins in prevention and the treatment of hyperlipidemia as well as regular bone density scans, calcium, vitamin D and bisphosphonate in management osteoporosis and avascular necrosis of the bone.

During the four-year follow-up, our patient was diagnosed as having one serious adverse effect - avascular necrosis of both femoral heads characterized by osseous cell death due to vascular compromise [11]. Corticoid treatment is the major risk factor which can lead to degenerative changes of the joints in SLE, however, AVN can occur in patients receiving a therapy which does not contain steroids [12].

The main goal of the evolution of a therapy in proliferative LN is to minimize toxicity and preserve efficacy through dose alterations and the introduction of new immunosuppressive agents such as an alternative to steroids, cyclophosphamide or MMF [7].

Inevitably, new therapies are being developed for lupus. New regiments: Calcineurin Inhibitors (Cyclosporine and Tacrolimus) and Biologics (Rituximab) as well as other anti-CD20 monoclonal

antibodies (Ocrelizumab, Ofatumumab, Epratuzumab, and TRU-015), Belimumab, Atacept, Abetimus and anticytokine therapies (monoclonal antibodies directed against INF- $\alpha$ , IL-1, IL-6, IL-10, TNF- $\alpha$ ) have emerged and show promising short term results. Nowadays we lean towards the individualization of therapy to maximize clinical improvement and reduce the risk of adverse effects [13].

## Conclusion

The classification based on glomerular pathology proved, in renal biopsy, determining the therapy of LN [4]. It should be emphasized that the clinical outcome of lupus nephritis is highly variable; particularly class IV-G is associated with a worse renal outcome [5].

KIDIGO published guidelines agreed that class IV requires aggressive therapy with glucocorticoids and immunosuppressive agents [7].

RPGM therapy among patients with SLE can be challenging, considering the lack of current treatment guidelines confirmed by data from well-conducted randomized trials. Presented case of RPGN in the background of SLE certified the double drug regimen consisting of steroid and immunosuppressive agent infusion as the most effective immunosuppressive medication. The favorable clinical outcome of our patient affirmed the necessity of urgently induced treatment as a prevention of irreversible kidney injury.

## Reference

- Jury EC, Kabouridis PS (2004) T-lymphocyte signaling in systemic lupus erythematosus: a lipid raft perspective. *Lupus* 13: 413-422.
- Cojocaru M, Cojocaru IM, Silosi I, Vrabie CD (2011) Manifestations of Systemic Lupus Erythematosus. *Maedica* 6: 330-336.
- Saxena R, Mahajan T, Mohan C (2011) Lupus nephritis: current update. *Arthritis Research & Therapy* 13: 240.
- Weening JJ, D'Agati VD, Schwartz MM, Seshan SV, Alpers CE, et al. (2004) The classification of glomerulonephritis in systemic lupus erythematosus revisited. *Kidney Int* 65: 521-530.
- Sada K-E, Makino H (2009) Usefulness of ISN/RPS Classification of Lupus Nephritis. *J Korean Med Sci* 24: S7-S10.
- Trager J, Ward MM (2001) Mortality and causes of death in systemic lupus erythematosus. *Curr Opin Rheumatol* 13: 345-351.
- (2012) KDIGO Clinical Practice Guideline for Glomerulonephritis. Chapter 12. Lupus nephritis (2012) *Kidney International Supplements* 2: 221-232.
- Brent LH (2015) Lupus Nephritis Treatment & Management *medscape.com*.
- Bose B, Silverman ED, Bargman JM (2014) Ten common mistakes in the management of lupus nephritis. *Am J Kidney Dis* 63: 667-676.
- Bono L, Cameron JS, Hicks JA (1999) The very long-term prognosis and complications of lupus nephritis and its treatment. *QJM* 92: 211-218.
- Stoica Z, Dumitrescu D, Popescu M, Gheonea I, Gabor M, et al. (2009) Imaging of avascular necrosis of femoral head: familiar methods and newer trends. *Curr Health Sci J* 35: 23-28.
- Dubois EL, Cozen L (1960) Avascular (Aseptic) Bone Necrosis Associated with Systemic Lupus Erythematosus. *JAMA* 174: 966-971.
- Hogan J, Appel GB (2013) Update on the treatment of lupus nephritis. *Curr Opin Nephrol Hypertens* 22: 224-230.

**Copyright:** © 2016 Jastrzębska K, et al. This is an open-access article distributed under the terms of the Creative Commons Attribution License, which permits unrestricted use, distribution, and reproduction in any medium, provided the original author and source are credited.

**Citation:** Jastrzębska K, Gozdowska J, Perkowska-Ptasińska A, Durlik M (2016) Rapidly Progressive Glomerulonephritis Associated with Systemic Lupus Erythematosus. *Arch Clin Nephrol* 2(1): 028-031