

Theodoros Empeslidis, Vasileios Konidaris, Periyasami Kumar, Somnath Banerjee, James Deane and Konstantinos T Tsaousis*

Ophthalmology Department, Leicester Royal Infirmary, Leicester LE1 5WW, UK

Dates: Received: June 25, 2014; Accepted: July 14, 2014; Published: July 16, 2014

***Corresponding author:** Konstantinos T Tsaousis, Ophthalmology Department, Medical Retina, Leicester Royal Infirmary, Infirmary Square, Leicester, Leicestershire, LE1 5WW, UK, Tel: +44116 258 5928; Fax: +44 258 6763; E-mail: konstantinos.tsaousis@gmail.com

www.peertechz.com

Keywords: Valacyclovir; Acute retinal necrosis; Chorioretinitis; Herpetic infection

ISSN: 2455-1414

Case Report

Valacyclovir as a Therapeutic Agent in Acute Retinal Necrosis: Two Case Reports

Abstract

Introduction: Acute retinal necrosis (ARN) is a rare, rapidly progressive viral retinitis. The current standard of care for ARN consists of intravenous acyclovir for 5-10 days, followed by oral acyclovir for an additional 6-12 weeks. Valacyclovir has superior plasma bioavailability to acyclovir as an oral preparation. The aim of this study is to add to the evidence of treating ARN with valacyclovir with 2 additional cases.

Methods: 2 patients diagnosed with ARN received treatment with valacyclovir either as a monotherapy, or in combination with intravenous acyclovir.

Results: All patients had significant improvement in visual acuity within 4 weeks of the initiation of treatment. In the sixth month follow-up none of them developed retinal detachment, which is one of the commonest sight-threatening complications of ARN.

Conclusions: Valacyclovir proved effective at treating retinitis in both patients. The 2 g t.i.d. dose was well tolerated and neither patient developed systemic adverse effects associated with the treatment.

Introduction

Acute retinal necrosis (ARN) is a rare, but potentially blinding disease, characterized by the clinical triad of vitreous inflammation, occlusive vasculopathy, and progressive peripheral retinal necrosis [1]. It took more than a decade after its first description for its herpetic aetiology to be discovered and antiviral therapy to become the mainstay of treatment [2,3]. ARN usually presents unilaterally, however, bilateral disease has been reported in up to 35% of patients [1]. The incidence in the UK is approximately 1 case per 1.6 to 2.0 million of population per year [4]. It usually affects immune-competent hosts, although it may occur in immuno-compromised individuals. As the outcome is often poor, prompt diagnosis and treatment prevents visual loss and involvement of the fellow eye. The clinical diagnosis is based on the standard diagnostic criteria proposed by the American Uveitis Society [5]. More recently, testing of aqueous or vitreous samples for viral DNA has identified varicella zoster virus (VZV), herpes simplex virus (HSV), Epstein-Barr virus (EBV) and occasionally cytomegalovirus (CMV) as the common causative agents of ARN [6,7]. Using polymerase chain reaction (PCR) methodologies, human herpes virus 6 (HHV6) has been recently implicated in ocular inflammation [8]. The state-of-the-art pattern of treatment for ARN involves intravenous acyclovir 10 mg/kg every 8 h for 5-10 days, subsequently oral acyclovir 400-800 mg 5 times daily for another 6-12 weeks, to decrease the possibility of second eye involvement [9]. Recent studies have reported that treatment with oral valacyclovir as the sole antiviral therapy resulted in favorable outcomes, with complete resolution of retinitis, a restoration of visual acuity, and a retinal detachment rate comparable with previously reported outcomes for intravenous acyclovir [9]. Moreover, high dosage of oral valacyclovir (2g 3 times/day) was suggested as an alternative

treatment of varicella zoster acute retinal necrosis syndrome, with good anatomic and functional results [10].

Valacyclovir and famciclovir have superior plasma bioavailability to acyclovir as oral preparations [11]. The aim of the present study is to add to this evidence with 2 additional cases of ARN treated with valacyclovir. Written informed consent was obtained from the patients for publication of these case reports and any accompanying images.

Case Presentation

Case report 1

A 22-year-old white male was referred to our Department with a 1 day history of floaters and blurred vision in his right eye. His medical history was remarkable following a diagnosis of glandular fever 4 weeks previously. Additionally, 10 days prior to presentation the patient had presented to the Neurology Department with widespread macular pruritic rash, sore throat, nausea, fever, headache, unsteadiness, weakness on the left leg, and binocular diplopia. At that time serology had confirmed an acute EBV infection with increased titres for EBV-IgM antibodies. Serological testing for Human Immunodeficiency Virus (HIV), hepatitis B and C, syphilis, HSV, VZV, and CMV was negative. A computerized tomography (CT scan) of the brain was unremarkable. However, analysis of cerebrospinal fluid (CSF) had revealed 97% lymphocytic cells, a protein level of 1.44 g/L and PCR had showed positive for HHV6 viral DNA (365 DNA copies/mL). CSF testing for HSV, VZV, EBV, CMV, and enterovirus was negative. In this setting, the patient had been diagnosed with HHV6 encephalitis and left fourth nerve palsy. He had been admitted under neurological care and treated with intravenous acyclovir (1 g 3 times daily for 10 days) and pulsed intravenous methylprednisolone (1g daily for 3 days).

On presentation, his best-corrected visual acuity (BCVA) was LogMAR 0.50 in the right eye and LogMAR 0.00 in the left eye with an intraocular pressure of 16 mmHg and 17 mmHg respectively. Additionally, a right relative afferent pupillary defect (RAPD) was present. Anterior segment examination revealed fine corneal precipitates on both eyes. The vitreous in the right eye showed minimal cellular infiltration. Fundoscopy of the right eye showed a well-demarcated creamy area of retinal necrosis in the lower periphery, and some oval-shaped confluent necrotic lesions scattered throughout the entire peripheral fundus (Figure 1). Inflammatory sheathing of retinal blood vessels was also evident. In the left eye some smaller multifocal whitish lesions and retinal vasculitis were identified. Since the patient was diagnosed with bilateral ARN and left post-viral 4th nerve neuropathy in the setting of HHV6 encephalitis, a diagnostic vitrectomy or anterior chamber tap was not performed, because this would have no therapeutic consequences. Given that the patient had already received intravenous acyclovir for 10 days, treatment was switched to oral valacyclovir (1g 3 times daily for 1 month) and oral prednisolone (60mg/day) for 10 days.

On follow-up examination after 4 weeks, retinal infiltration had significantly improved and peripheral retinal scarring had started to develop (Figure 2). His visual acuity had improved to LogMAR 0.00 on both eyes.

Case report 2

A 62-year-old white female presented in the emergency department of the Ophthalmology Clinic with sudden onset of floaters in her left eye. She was immuno-suppressed, on tablets of cyclosporin (100 mg/day) after a recent bone marrow transplant for acute myeloid leukaemia. BCVA of the right eye was LogMAR 0.2 and of the left eye LogMAR 0.3. Intraocular pressures were 16 and 25 mmHg respectively. Examination of the right eye was unremarkable. On examination of her left eye the pupil was mid-dilated, with a positive RAPD. Keratic precipitates were present, as well as 3+ of anterior chamber cellular activity. Fundoscopy showed a dense vitreous condensation, vitritis 3+, and occluded retinal arteries with segmentation. Fundus fluorescein angiography (FFA) demonstrated the presence of Kyrleis plaques. Serological testing was positive for CMV (IgG 18.2 g/L and IgM 2.56 g/L, with normal ranges of 6.0-16 g/L and 0.5-2.0 g/L respectively) and negative for HIV, hepatitis B and

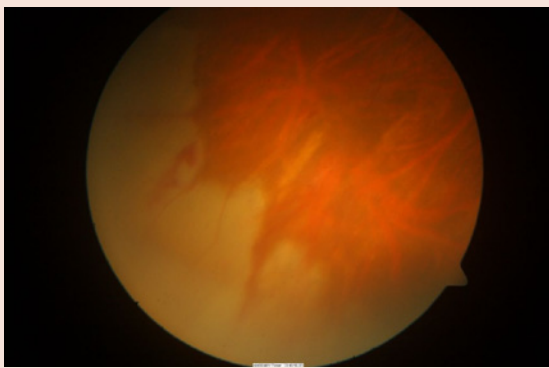


Figure 1: Fundoscopy of the right eye at presentation, showing peripheral necrotising retinitis (Case 1).

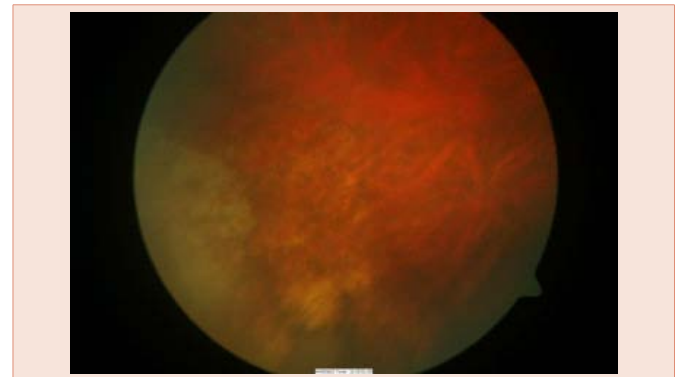


Figure 2: Fundoscopy of the right eye after 4 weeks, showing improvement of retinal infiltration and peripheral scarring (Case 1).

C, syphilis, HSV, VZV. The patient was treated with 2 g of valacyclovir 3 times/day. On examination 2 weeks after the initiation of treatment, BCVA of the left eye improved to LogMAR 0.2, intraocular pressure decreased to 16 mm Hg, the cornea was clear and anterior chamber cellular activity decreased to 1+. Fundoscopy showed the presence of debris, as well as segmented arteritis (Figure 3). Valacyclovir was discontinued 3 months after initiation of treatment, and the patient remains asymptomatic, with her vision remaining stable.

Discussion

ARN is a rare, rapidly progressive retinitis caused by herpes viruses. Retinal necrosis is thought to result from the combined effect of intracellular viral replication with subsequent cell death and vascular occlusion secondary to acute vasculitis [1]. The major causes of poor functional outcome in ARN are rhegmatogenous retinal detachment, and optic nerve or macular involvement by ischemic vasculopathy [6]. It usually occurs in immuno-competent hosts, but has been also reported in immuno-compromised patients with autoimmune disorders, organ transplants, cancer and HIV infection [7]. The current standard treatment for ARN consists of intravenous acyclovir, followed by oral acyclovir [9]. In other studies [12,13], the use of the oral drugs valacyclovir and famciclovir resulted in the complete regression of ARN caused by herpes viruses. In a recent study by Taylor et al. (2014), treatment with oral valacyclovir as monotherapy resulted in favorable outcomes, with the complete resolution of retinitis and visual acuity, and a retinal detachment rate comparable with previously reported outcomes for intravenous acyclovir [9].

In this article, we report the results of treatment of ARN with oral valacyclovir. In the first case the patient was treated with acyclovir for 10 days and in the second case for 5 days before switching to valacyclovir. In the second case treatment was initiated with valacyclovir. Our experience with valacyclovir is continuously improving and, therefore, we felt more confident in using this drug solely as monotherapy [14]. Valacyclovir proved effective at treating retinitis in both patients.

Contralateral ARN is well described in cases with Herpes Zoster Ophthalmicus [15]. Second eye involvement occurs in approximately a third of patients, typically within 6 weeks, although fellow eye involvement decades following an initial infection have been

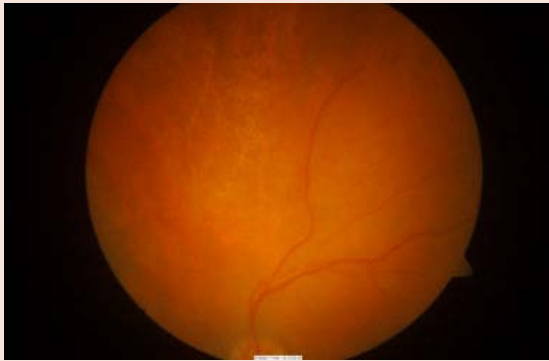


Figure 3: Colour fundus photograph of the left eye presenting occluded retinal arteries with segmentation (Case 2).

described [16]. The natural history of ARN is for 75% of affected eyes to progress to retinal detachment [17], the reported rate with intravenous acyclovir being reduced to 20-52% [7,18-21]. Most retinal detachments occur within 6 months of presentation [20]: our patients had follow-up examinations longer than 6 months, suggesting that the risk of retinal detachment is significantly reduced. Interestingly, necrotizing herpetic retinopathies, described as a new spectrum of diseases induced by viruses of the herpes family can lead to ARN occurring in immuno-competent patients and progressive outer retinal necrosis in severely immuno-compromised patients [22]. The role of the host immune system has, therefore, been suggested as a factor leading to the progression of the disease.

We treated our patients with oral valacyclovir 2 g t.i.d. on the basis that this would be as efficient as intravenous acyclovir 10 mg/kg t.i.d. without exposing patients to the side-effects associated with higher doses of valacyclovir, which include the development of thrombotic microangiopathy [23] and without compromising patient compliance throughout long treatment duration [24]. The 2 g t.i.d. dose was well tolerated in our patients, and no patient developed systemic adverse effects associated with treatment.

Conflict of Interest

None of the authors has any financial or proprietary interest in any materials or methods described herein.

References

- Garty DS, Spalton DJ, Tilzey A, Hykin PG (1991) Acute retinal necrosis syndrome. *Br J Ophthalmol* 75: 292-297.
- Blumenkranz MS, Culbertson WW, Clarkson JG, Dix R (1986) Treatment of the acute retinal necrosis syndrome with intravenous Acyclovir. *Ophthalmology* 93: 296-300.
- Culbertson WW, Blumenkranz MS, Haines H, Gass DM, Mitchell KB, et al. (1982) The acute retinal necrosis syndrome. Part 2: Histopathology and etiology. *Ophthalmology* 89: 1317-1325.
- Muthiah MN, Michaelides M, Child CS, Mitchell SM (2007) Acute retinal necrosis: a national population-based study to assess the incidence, methods of diagnosis, treatment strategies and outcomes in the UK. *Br J Ophthalmol* 91: 1452-1455.
- Holland GN (1994) Standard diagnostic criteria for the acute retinal necrosis syndrome. Executive Committee of the American Uveitis Society. *Am J Ophthalmol* 117: 663-667.
- Hillenkamp J, Nolle B, Bruns C, Rautenberg P, Fickenscher H, et al. (2009) Acute retinal necrosis: clinical features, early vitrectomy, and outcomes. *Ophthalmology* 116: 1971-1975.
- Lau CH, Missotten T, Salzmann J, Lightman SL (2007) Acute retinal necrosis features, management, and outcomes. *Ophthalmology* 114: 756-762.
- Sugita S, Shimizu N, Watanabe K, Ogawa M, Maruyama K, et al. (2012) Virological analysis in patients with human herpes virus 6-associated ocular inflammatory disorders. *Invest Ophthalmol Vis Sci* 53: 4692-4698.
- Taylor SR, Hamilton R, Hooper CY, Joshi L, Morarji J, et al. (2012) Valacyclovir in the treatment of acute retinal necrosis. *BMC Ophthalmol* 12: 48.
- Guex-Crosier Y, Meylan PR (2006) High dosage of oral valaciclovir as an alternative treatment of varicella zoster acute retinal necrosis syndrome. *Eye (Lond)* 20: 247.
- Soul-Lawton J, Seaber E, On N, Wootton R, Rolan P, et al. (1995) Absolute bioavailability and metabolic disposition of valaciclovir, the L-valyl ester of Acyclovir, following oral administration to humans. *Antimicrob Agents Chemother* 39: 2759-2764.
- Aizman A, Johnson MW, Elner SG (2007) Treatment of acute retinal necrosis syndrome with oral antiviral medications. *Ophthalmology* 114: 307-312.
- Aslanides IM, De Souza S, Wong DT, Giavedoni LR, Altomare F, et al. (2002) Oral valacyclovir in the treatment of acute retinal necrosis syndrome. *Retina* 22: 352-354.
- Empeslidis T, Konidaris V, Brent A, Vardarinos A, Deane J (2013) Kyrieleis plaques in herpes zoster virus-associated acute retinal necrosis: a case report. *Eye (Lond)* 27: 1110-1112.
- Fisher JP, Lewis ML, Blumenkranz M, Culbertson WW, Flynn HW Jr, et al. (1982) The acute retinal necrosis syndrome. Part 1: Clinical manifestations. *Ophthalmology* 89: 1309-1316.
- Martinez J, Lambert HM, Capone A, Sternberg P Jr, Aaberg TM, et al. (1992) Delayed bilateral involvement in the acute retinal necrosis syndrome. *Am J Ophthalmol* 113: 103-104.
- Carney MD, Peyman GA, Goldberg MF, Packo K, Pulido J, et al. (1986) Acute retinal necrosis. *Retina* 6: 85-94.
- Meghpara B, Sulkowski G, Kesen MR, Tessler HH, Goldstein DA (2010) Long-term follow-up of acute retinal necrosis. *Retina* 30: 795-800.
- Sims JL, Yeoh J, Stawell RJ (2009) Acute retinal necrosis: a case series with clinical features and treatment outcomes. *Clin Experiment Ophthalmol* 37: 473-477.
- Tibbetts MD, Shah CP, Young LH, Duker JS, Maguire JI, et al. (2010) Treatment of acute retinal necrosis. *Ophthalmology* 117: 818-824.
- Wong R, Pavesio CE, Laidlaw DA, Williamson TH, Graham EM, et al. (2010) Acute retinal necrosis: the effects of intravitreal foscarnet and virus type on outcome. *Ophthalmology* 117: 556-560.
- Guex-Crosier Y, Rochat C, Herbort CP (1997) Necrotizing herpetic retinopathies. A spectrum of herpes virus-induced diseases determined by the immune state of the host. *Ocul Immunol Inflamm* 5: 259-265.
- Bell WR, Chulay JD, Feinberg JE (1997) Manifestations resembling thrombotic microangiopathy in patients with advanced human immunodeficiency virus (HIV) disease in a cytomegalovirus prophylaxis trial (ACTG 204). *Medicine (Baltimore)* 76: 369-380.
- Vigil KJ, Chemaly RF (2010) Valacyclovir: approved and off-label uses for the treatment of herpes virus infections in immunocompetent and immunocompromised adults. *Expert Opin Pharmacother* 11: 1901-1913.

Copyright: © 2014 Empeslidis T, et al. This is an open-access article distributed under the terms of the Creative Commons Attribution License, which permits unrestricted use, distribution, and reproduction in any medium, provided the original author and source are credited.

Citation: Empeslidis T, Konidaris V, Kumar P, Banerjee S, Deane J, et al. (2014) Valacyclovir as a Therapeutic Agent in Acute Retinal Necrosis: Two Case Reports. *J Clin Res Ophthalmol* 1(1): 016-018. DOI: 10.17352/2455-1414.000004