

Neslihan Sevimli<sup>1</sup>, Remzi Karadag<sup>2\*</sup>,  
Bahri Aydin<sup>3</sup>, Müferret Ergüven<sup>4</sup> and  
Hüseyin Bayramlar<sup>5</sup>

<sup>1</sup>Department of Ophthalmology, Istanbul Medeniyet University Goztepe Research and Training Hospital, Goztepe, Istanbul, Turkey

<sup>2</sup>Department of Ophthalmology, Associate Prof., Istanbul Medeniyet University, Faculty of Medicine, Goztepe, Istanbul, Turkey

<sup>3</sup>Department of Ophthalmology, Associate Prof., Istanbul Medeniyet University, School of Medicine, Goztepe, Istanbul, Turkey

<sup>4</sup>Department of Pediatrics, Prof., Istanbul Medeniyet University Goztepe Research and Training Hospital, Goztepe, Istanbul, Turkey

<sup>5</sup>Department of Ophthalmology, Prof., Istanbul Medeniyet University, School of Medicine, Goztepe, Istanbul, Turkey

**Dates:** Received: 24 October, 2014; Accepted: 08 January, 2015; Published: 10 January, 2015

\*Corresponding author: Remzi Karadag, MD, Associate Prof., Istanbul Medeniyet University, Faculty of Medicine, Department of Ophthalmology, Goztepe, Istanbul, TURKIYE, Tel: +90 216 2803333; Fax: +90 216 6022800; E-mail: drkaradag@yahoo.com

www.peertechz.com

**Keywords:** Familial mediterranean fever; Loss of vision; Multiple sclerosis; Papilledema; Retinal hemorrhages

ISSN: 2455-1414

## Case Report

# Eye Involvement as the Initial Sign of Multiple Sclerosis in a Case with Familial Mediterranean Fever

### Abstract

**Purpose:** To present a case of familial Mediterranean fever with eye involvement as the initial sign of multiple sclerosis.

**Method:** A 13-year-old boy with familial mediterranean fever (FMF) presented with sudden loss of vision in his right eye.

**Findings:** Visual acuity was 50 cmfc (centimeter finger counting) in the right eye associated with papilledema and intraretinal **Hemorrhages:** Magnetic resonance imaging (MRI) scans revealed a hyper-intense lesion in left occipital lobe. Two days later, left eye was also affected, while the right eye began to deteriorate. In control MRI, lesions were observed to have deteriorated with the involvement of right occipital lobe and pons in addition to the left occipital lobe. Patient was diagnosed with multiple sclerosis (MS) due to FMF and was hospitalized. After a 2-weeks-treatment of steroid and immunoglobulin (Ig), visual acuity improved; fundus findings regressed.

**Conclusion:** Eye involvement may be the first sign of MS in a case of established FMF.

with FMF patients and these patients can manifest with neurological symptoms especially in young adult [4]. To the best of our knowledge, this is the first case report of MS associated with FMF which manifests with eye involvement.

## Case Report

A 13 year old boy with the diagnosis of FMF since the age of 5 had been successfully treated with colchicine. He had a sister who also had FMF. He presented with headache and blurry vision in the right eye, which had started one week prior to his admission. Visual acuity was 50 cmfc in the right eye and 1.0 in the left eye taken by snellen chart. No abnormality was detected in the left eye. The right optic disc was edematous and associated with the enlargement of the retinal veins and small retinal hemorrhages. Fundus fluorescein angiography revealed optical disc leakage. The right eye showed a relative afferent pupillary defect. A well-defined hyper-intense lesion was detected in the left occipital region in MRI and the patient was hospitalized. Two days later, visual acuity was reduced to no light perception in the right eye and to 50 cmfc in left. Both of the optic discs were reddish and swollen. There were macular and intra retinal hemorrhages and varicose enlargement of retinal veins (Figure 1).

Control MRI scans showed a new lesion in right occipital lobe; multiple and increased hyper intense lesions in both occipital lobes and pons without contrast enhancement on the T2 weighted images compatible with MS. Analysis of the cerebrospinal fluid (CSF) revealed a pressure of 23 cm H<sub>2</sub>O, 16 leucocytes (90% of polymorphonuclear neutrophilic leukocytes), 76 mg/ml of glucose and 53 mg/ml of protein. Both CSF and serum were positive for oligoclonal bands. Borrelia burgdorferi IgG and IgM, anti rubella IgG results were negative. CRP, sedimentation, homocysteine levels were

## Introduction

Familial Mediterranean fever (FMF) is a common hereditary auto-inflammatory disease characterized by recurrent and self-limited attacks of serosal inflammation. The disease demonstrates an autosomal recessive inheritance pattern. Serositis can be observed as abdominal pain (peritonitis), chest pain (pleuritis) and joint pain (arthritis) usually accompanied by fever. The disease is more prevalent among the people living in the Middle East and Mediterranean regions. The prevalence ranges from 1/250 to 1/1000 depending upon the geographic locations [1]. Reports of ophthalmological manifestations in FMF are few and include retinal changes, panuveitis, anterior uveitis, scleritis, and episcleritis [2].

Multiple Sclerosis (MS) is a disease of the central nervous system characterized by multiple areas of inflammation and demyelination in the white matter of the brain and spinal cord [3]. Common neuro-ophthalmologic manifestation of MS is unilateral and painful vision loss due to optic neuritis. This is the first manifestation of MS, and usually appears as single-sided retrobulbar optic neuritis. Ocular motor deficits in multiple sclerosis include inter nuclear ophthalmoplegia (INO) and nystagmus, resulting in diplopia, oscillopsia, blurred vision, loss of stereopsis, and reading fatigue [3].

Central nervous system manifestations are rare in FMF, but in some cases, similar genetic susceptibility, environmental factors and described pathophysiological events show that MS may be associated

normal. Doppler ultrasonography of lower extremities and carotid arteries and echocardiography were within normal limits. Systemic administration of an antiviral agent (acyclovir 1500 mg/day, oral), an antibacterial agent (ceftriaxone 4 gr/day, intravenously) and corticosteroids (prednisolone 1 gr/day, intravenously) were started for suspected infection and vasculitis.

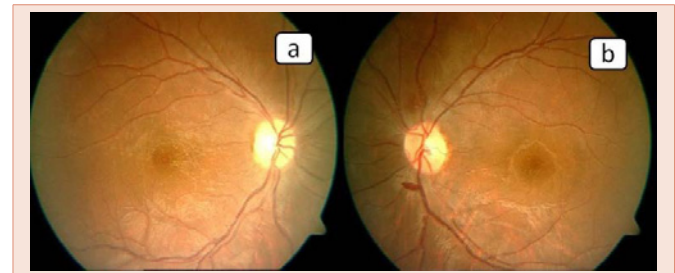
Five days later, visual acuity was light perception in the right, and 1 mfc in the left eye. Immunoglobulin (IVIG) 15 gr/5days was started, intravenously.

Four days after IVIG therapy, control cranial MR and MR venography were taken. A significant regression in the lesions of right and left occipital lobes and pons was noted. Two days later, visual acuity was light perception in the right eye and 3 mfc in the left. The borders of the optic nerve was back to normal in the examination of the fundus. In the ophthalmoscopic examination, no papilledema was detected. However, intra retinal haemorrhages were still present in both eyes.

The patient was discharged with oral prednisolone 1.5 mg/kg/day (60 mg/day) and colchicine 1.5 mg/day, IVIG, cyclophosphamide 500 mg/day and canakinumab planned to begin. One month later, right and left eyes had Snellen acuity of 0.7 and 1.0, respectively. The patient's general status was stable after 8 months follow-up period (Figure 2).

## Discussion

Acute FMF attacks are associated with a nonspecific increase in inflammatory mediators, such as serum amyloid A (SAA), fibrinogen, erythrocyte sedimentation rate (ESR), C-reactive protein (CRP) and interleukin 1 beta (IL-1  $\beta$ ). So, FMF may be associated with some inflammatory diseases such as spondyloarthritis, multiple sclerosis, ulcerative colitis, and various systemic vasculitis [5]. In patients with FMF, occurrence of these comorbidities is higher than in the general population. On the other hand, neurological involvement is rare in



**Figure 2:** Right (a) and left (b) eyes fundus appearances after treatment.

FMF [6] and usually occurs due to central nervous system (CNS) complications of polyarteritis nodosa, vasculitis, hypercoagulable states secondary to renal amyloidosis, recurrent aseptic meningitis, amyloid ophthalmoplegia, neuro-Behçet disease or MS [7].

FMF is caused by mutations in Mediterranean Fever (MEFV) gene, which encodes pyrin protein. Occurrence of pyrin mutations in MS patients is higher than in the general population. Also MS patients with MEFV mutation seem to have susceptibility to develop a more progressive disease [8]. Especially the pyrin E148Q mutation is a potential risk factor for MS [9]. Pyrin is a kind of protein responsible for the regulation of apoptosis and inflammation. Mutated pyrin is associated with increased production of IL-1 $\beta$ . IL-1 plays a significant role in the regulation of the T-cells, while changes in T-cell function play a role in the formation of MS [10]. Also, this increased inflammation might lead to vascular co-morbidities in FMF patients and carriers of the MEFV mutation. Vascular changes like endothelial dysfunction may cause deterioration of blood-brain barrier and facilitates the formation of MS lesions [10].

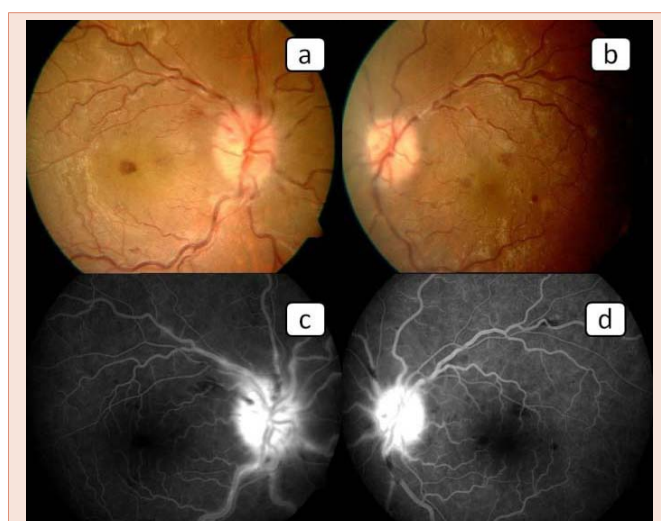
Multifocal hiperintense demyelinating plaques were seen in T2 weighted MRI and oligoclonal IgG bands were positive in CSF. Together with the improvement in the condition of the patient under treatment, these findings confirmed the diagnosis of MS. Ocular findings are rare and not clear in FMF. On the other hand, MS is usually presented with retrobulbar optic neuritis [3]. The co-existence of FMF and MS is well established in the literature [6-8]. However, this is the first case of co-existence of FMF and MS who presented with sudden vision loss. Compared to other series of FMF and MS, our patient appears to be the youngest patient [1,4,6,7]. For the scope of the study it is important to note that we could not perform gene mutation due to lack of technical equipment and staff.

## Conclusion

We must keep in mind that MS findings could be seen in children with FMF. The patients may present with different ocular findings which might be the first referred sign.

## References

- Ugurlu S, Bolayir E, Candan F, Gumus C (2009) Familial mediterranean fever and multiple sclerosis-a case report. *Acta Reumatol Port* 34: 117-119.
- Karalezli A, Borazan M, Yilmaz S, Kiyici H, Akova YA (2009) Conjunctival impression cytology and tear-film changes in patients with familial Mediterranean fever. *Acta Ophthalmol* 87: 39-43.
- Pfriem M, Ababneh L, Schittkowski MP (2012) Ophthalmological Findings in



**Figure 1:** Right (a) and left (b) eyes were papilledema, intra retinal hemorrhages, dilatation of the veins. In fundus fluorescein angiography; right (c) and left (d) eyes were optical disc leakage.



- Paediatric and Adolescent Multiple Sclerosis. *Klin Monbl Augenheilkd* 229: 1021-1023.
4. Akman-Demir G, Gul A, Gurol E, Ozdogan H, Bahar S, et al. (2006) Inflammatory/ demyelinating central nervous system involvement in familial Mediterranean fever (FMF): coincidence or association? *J Neurol* 253: 928-934.
  5. Aksu K, Keser G (2011) Coexistence of vasculitides with familial Mediterranean fever. *Rheumatol Int* 31: 1263-1274.
  6. Guinet A, Grateau G, Nifle C, Rozier A, Pico F (2008) Multiple sclerosis and familial Mediterranean fever: a case report. *Rev Neurol (Paris)* 164: 943-947.
  7. Topcuoglu MA, Karabudak R (1997) Familial Mediterranean fever and multiple sclerosis. *J Neurol* 244: 510-514.
  8. Unal A, Dursun A, Emre U, Tascilar NF, Ankarali H (2010) Evaluation of common mutations in the Mediterranean fever gene in Multiple Sclerosis patients: is it a susceptibility gene? *J Neurol Sci* 294: 38-42.
  9. Kümpfel T, Gerdes LA, Wacker T, Blaschek A, Havla J, et al. (2012) Familial Mediterranean fever-associated mutation pyrin E148Q as a potential risk factor for multiple sclerosis. *Mult Scler* 18: 1229-1238.
  10. Alpayci M, Bozan N, Erdem S, Gunes M, Erden M (2012) The possible underlying pathophysiological mechanisms for development of multiple sclerosis in familial Mediterranean fever. *Med Hypotheses* 78: 717-720.

**Copyright:** © 2015 Sevimli N, et al. This is an open-access article distributed under the terms of the Creative Commons Attribution License, which permits unrestricted use, distribution, and reproduction in any medium, provided the original author and source are credited.

**Citation:** Sevimli N, Karadag R, Aydin B, Ergüven M, Bayramlar H (2015) Eye Involvement as the Initial Sign of Multiple Sclerosis in a Case with Familial Mediterranean Fever. *J Clin Res Ophthalmol* 2(1): 010-012. DOI: 10.17352/2455-1414.000009