

Mohammad Hossein Davari<sup>1\*</sup> and Hoda Gheytsi<sup>2</sup>

<sup>1</sup>Birjand Atherosclerosis and Coronary Artery Research Center, Assistant Professor of Ophthalmology, Birjand University of Medical Science, Birjand, Iran

<sup>2</sup>Department of Genetic, PhD student of genetic at University of Barcelona translational research, laboratory2 Hospital Duran I Reynolds

**Dates:** Received: 19 December, 2014; Accepted: 16 March, 2015; Published: 18 March, 2015

**\*Corresponding author:** Mohammad Hossein Davari, Ophthalmology Department, Valli Asre Hospital, Birjand University of Medical Science, South Khorassan, Ghaffari Street Birjand, Iran, E-mail: mhd\_1337@yahoo.com

[www.peertechz.com](http://www.peertechz.com)

**Keywords:** Wart; Uper lid; Lower lid

**ISSN:** 2455-1414

## Case Report

# Bilateral Numerous Warts in Upper and Lower Eyelids, in Middle-Aged Man

### Abstract

**Background:** Warts are small, usually painless growths on the skin caused by a virus called human papillomavirus (HPV). Most, but not all, are generally harmless [1,2].

Warts can be disfiguring and embarrassing. Sometimes they itch or hurt (particularly on the feet). Some warts spread through sex. But in The eyelids are rare. Viral warts are a common skin condition, which can range in severity from a minor nuisance that resolve spontaneously to a troublesome, chronic condition [3-5]. Many different treatments are available but because warts were very large, we use a surgical procedure (excision).

**Purpose:** To evaluate the efficacy of cut out the wart (excision) by surgery.

**Materials/Patients:** In this case report, 56 years old man have been reported with upper and lower eyelid involvement in both eyes. Expressed warts came the age of 20 and around the eyelids of both eyes and then grows within 5 years, Sized warts at presentation were 1 to 5 mm until warts on eyelids make adverse effects on vision. Warts were also seen around the patient's neck. He had no other illnesses. The patient's mother had two warts 4 to 5 mm around her nose. We have treated the warts eye in vali Asr hospital, Birjand University of Medical Sciences. Pathologist also reported Verruca Vulgarism. Patient after surgery was visit in terms of recurrence and fortunately it was not a problem.

## Discussion

Common warts can be annoying to anyone. It is worth considering that, in normal people, half of all warts, on average, spontaneously go away within about 18 months.

We have treated the warts eye in vali Asr hospital, Birjand University of Medical Sciences. Because the location and number of warts around the eyes were large, other treatments are not appropriate, so we chose a surgical procedure. Despite of more treatments about warts including: Cryotherapy, cantharidin, Electro surgery and curettage, Laser, Chemical peels... We use a surgical procedure because warts were very large (excision).

We cut out the warts with sharp knife completely in local anesthesia, Pathologist also reported Verruca Vulgarism. Still has not recurred after 18 months (Figures 1-6).

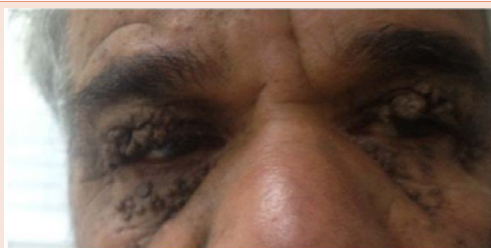


Figure 1:

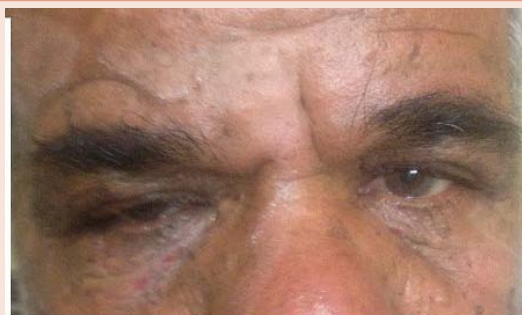

Figure 2:

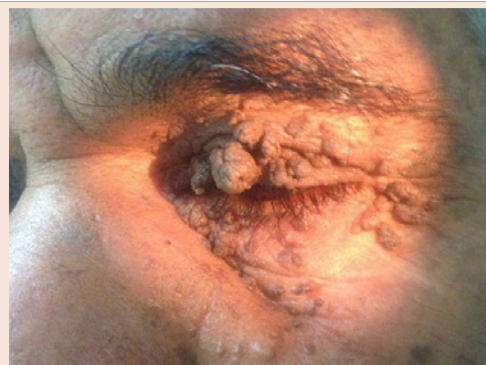

Figure 3:

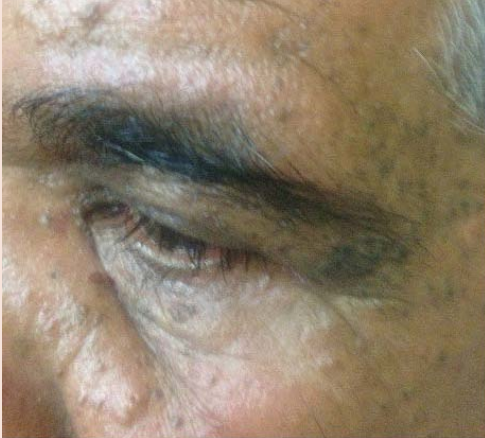

Figure 4:

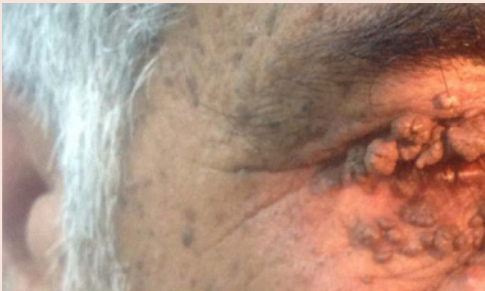

Figure 5:

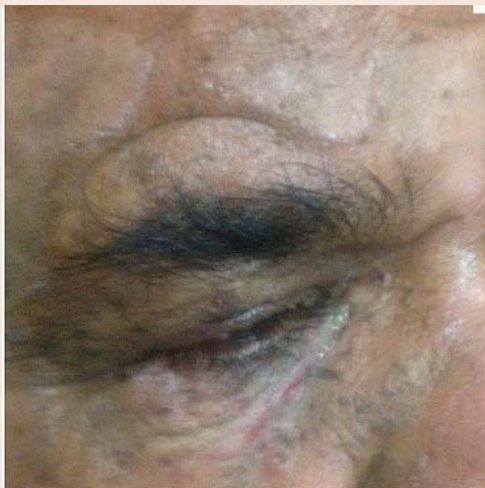

Figure 6:

## Conclusion

Conclusion: Bilateral eye lids involvement of multiple warts are rare but they can often be treated successfully by surgical incision without recurrence.

## References

1. Warts, herpes simplex, and other viral infections. In: Habif TP, ed. *Clinical Dermatology*. 5th ed. Philadelphia, Pa: Mosby Elsevier; 2009:chap 12.
2. Myer CM 3<sup>rd</sup>, Woodruff SM (1983) Pathologic quiz case 2. Squamous papilloma of the external auditory canal. *Arch Otolaryngol* 109:200-1, 203.
3. Nager GT (1993) Neoplasms and other lesions of the external ear. In: *Pathology of the ear and temporal bone*. Baltimore: Williams & Wilkins 387–412.
4. Hyams VJ, Batsakis JG, Michaels L (1988) In: *Atlas of tumor pathology. Tumors of the upper respiratory tract and ear*. 2nd series. Fascicle 25. Washington DC: AFIP 260–261.
5. Mills SE, Gaffey MJ, Frierson JR (2000) HF. In: *Atlas of tumor pathology. Tumors of the upper aerodigestive tract and ear*. 3rd series. Fascicle 26. Washington DC: AFIP 408–409.
6. Yadav SP, Chandra R, Goyal N (2002) Aural papillomatosis in a 3-year-old child. *Int J Pediatr Otorhinolaryngol* 66:185–187.
7. Dickson RI, Worth AJ (1978) Malignant squamous papillomatosis of the mastoid. *J Otolaryngol* 7:283–288.
8. Block SL, Nolan T, Sattler C (2006) Comparison of the immunogenicity and rectogenicity of prophylactic quadrivalent human papillomavirus (types 6, 11, 16, and 18) L1 virus-like particle vaccine in male and female adolescents and young adult women. *Pediatrics* 118:2135–2145.
9. Markowitz LE, Dunne EF, Saraiva M (2007) Quadrivalent human papillomavirus vaccine. Recommendations of the Advisory Committee on Immunization Practices (ACIP) *MMWR Recomm Rep* 56:1–24.
10. Gibbs S (2006) Topical treatments for cutaneous warts. *Cochrane Database Syst Rev*(3):CD001781.

**Copyright:** © 2015 Davari MH, et al. This is an open-access article distributed under the terms of the Creative Commons Attribution License, which permits unrestricted use, distribution, and reproduction in any medium, provided the original author and source are credited.

**Citation:** Davari MH, Gheytsi H (2015) Bilateral Numerous Warts in Upper and Lower Eyelids, in Middle-Aged Man. *J Clin Res Ophthalmol* 2(3): 031-032. DOI: 10.17352/2455-1414.000016