

Ufuk Cobanoglu^{1*} and Selvi Asker²¹Department of thoracic surgery, Medical Faculty, Doctor of medicine, Associate Professor, University of Yuzuncu Yil, Van, Turkey²Department of pulmonology, Medical Faculty, Doctor of medicine, Assistant Professor, University of Yuzuncu Yil, Van, Turkey**Dates:** Received: 05 May, 2015; Accepted: 26 May, 2015; Published: 29 May, 2015***Corresponding author:** Ufuk Cobanoglu, Department of thoracic surgery, Medical Faculty, Doctor of medicine, Associate Professor, University of Yuzuncu Yil, Van, Turkey, Tel: +905362199397; E-mail: drucobanoglu@hotmail.comwww.peertechz.com

ISSN: 2454-2968

Keywords: Hydatid cyst; Lung; Complication

Review Article

Complications of Hydatid Cysts in the Lung

Abstract

A hydatid cyst, or echinococcus, is a zoonosis frequently formed by the larvae of *Echinococcus granulosus*. The disease appears as a slowly growing cystic mass and is asymptomatic. The disease is common in the Eastern, Southeastern, and Central Anatolia regions of Turkey. The rate of incidence of the disease in Turkey is reported as 5.7 out of 100,000 individuals. The complications of hydatid cysts appear as different clinical entities depending on the cyst's being intact or ruptured. The complications of intact cysts are usually compression symptoms, while the infection in the clinical progress of the ruptured cysts and secondary complications to the infection are frequently seen. In this section, hydatid cyst complications in the lung, extrapulmonary thoracic findings, and respiratory system complications of hydatid cyst cases of the liver will be discussed.

Introduction

Echinococcus is one of the common infections around the world caused by adult parasites of the *Echinococcus* species in the final hosts and the larva with metacestode form in the interval hosts. Infections in the final hosts are called echinococcus while the infection caused by the larva in interval host is called echinococcus, hydatid cyst disease, hydatidosis, cystic echinococcus, alveolar echinococcus, and polycystic echinococcus [1].

Hydatid cyst disease, which is common throughout the world, remains a serious health problem in developing countries and in the countries where stock-breeding is common [2].

It adheres to the intestinal wall with the embryo caranoids from the eggs taken orally and reaches the liver, first entering the blood vessels there. Therefore, the organ where the disease is seen at the most frequent rate is the liver, at a rate of 60-70%. 20 to 25% of the patients have lung involvement and 10% have any organ involvement. When the parasite settles on an organ, hydatid cysts occurs [3].

There are 4 means through which the parasite can reach the lung: 1-The parasite dies, there is a loss of liquid, and the cuticula get fibrosis; 2-The cysts is expectored through bronchial drainage; 3. The infection between the cyst and cuticula leads to cystic death and infection appears in the space; and 4. The cysts continue growing depending on the resistance of lung surrounding [4].

Cysts hydatid can present with many different clinical findings since it may have various organ involvements and also due to the complications that may develop. The objective of this paper is to review the complications that may occur during the progress of the hydatid cysts in the lung and the clinical findings that develop in line with these complications.

Additionally, extrapulmonary intrathoracic hydatid cyst cases and the respiratory system complications developed based on the hydatid cysts in the liver will be discussed in this section.

The complications of hydatid cysts in the lung can be generally discussed under nine headings.

Complications of Intact Cysts

The early period of the formation of a cyst is generally asymptomatic and they do not exhibit any symptoms until they reach nearly 5 cm in diameter [3]. The cysts without symptoms are generally detected during regular treatments [3].

The symptoms appear with pressure on the adjacent organs and the development of complications. Hydatid cysts can reach to large dimensions (≥ 10 cm) without symptoms in the pediatric age groups since their immune response has not yet fully developed; furthermore, the parenchyma elasticity of the lung and the respiratory capacity is greater compared to adults [5]. Such cysts generally lead to chest pain and coughing, depending on bronchial and/or pleural irritation and to dyspnea, depending on the pressure on the parenchyma [5].

Larger cysts may lead to the symptoms due to pressure on the adjacent vital organs, such as the esophagus, heart, trachea, and large veins and may cause mediastinal shift, cardiac malposition and arrhythmia, pressure on the main vascular structures, and Vena Cava Superior Syndrome [6].

In our multi-centered study in which we examined hydatid cyst cases with 412 cases between 2003 and 2011, giant hydatid cyst was detected in 46 cases (11.1%) and mediastinal shift and the clinical findings depending on this were detected in 9.75% of the cases [7].

After the diagnosis, the patients were scheduled for urgent surgery (Figure 1).

Atelectasis caused by compression of the cyst and pneumonia as a result of atelectasis are the common complications in cases of intact cysts [6,8]. In intact cysts, pneumonia developing from atelectasis is formed as a result of the erosion of the bronchus by the cysts, cyst rupture, or more rarely, erosion occurring in the vascular structure [6,8]. The cysts in the lungs were reported to cause massive hemoptysis and subsequent mortality when they are closely adjacent to large vascular structures and the vascular wall is eroded [8]. In our multi-centered study it was detected that atelectasis depending on hydatid cyst pressure developed in 16.26% of the cases (11.6% of

these cases are with giant hydatid cyst) and the respiratory problems increased [7]. In the same study [7], the presence of pneumonia was detected during the diagnosis in 3.39% of the cases. However, in another of our studies where diagnosis dilemma in cystic hydatid cases was examined [9], it was determined that 27.27% of the cases were tracked with lobar pneumonia and following the treatments, the presence of a hydatid cyst was detected (Figure 2).

Since the fibrosed lung parenchyma forms the pericystic tissue around the growing hydatid cyst, parenchymal loss is in direct proportion to the size of the cyst [6]. Bronchiectasis in the distal parenchyma as a result of bronchial obstruction and a destroyed lung are the other frequently seen complications. If the parenchymal destruction is considered to be irrevocable in such cases, resection must be preferred [6,10]. In the current study, the destruction areas of which the borders exist and do not exist in the anatomic localization, in the peripheral parenchymal tissue in many cases with hydatid cyst were detected while destroyed lung covering the entire lung was not detected in any case. In three cases related to hydatid cyst (0.72%), it was detected that the bronchiectasis developed and anatomic resections were conducted on these cases [7].

Complications Related to Hydatid Cyst Rupture

Hydatid cysts may be ruptured to the bronchial system at any period of the life cycle, whether spontaneous iatrogenic, or traumatic [11]. Perforation rates in lung hydatid cysts may vary between 26.7-49% in different series [6,11]. In our studies, the perforation rate was high (42.7%) because of late consultation with a doctor due to the socio-economic and cultural structure of the region [7,12] (Figures 3, 4).

Since the pericystic in the lung does not develop well as in the liver, it is more likely to rupture. An increase in the size of the cyst, which causes an increase in intrathoracic pressure, due to factors such as trauma and cough, can cause the cyst rupture [11]. The pressure inside the cyst is proportional to the cube of the diameter of the cyst. Therefore, even the smallest increase in diameter of the cyst increases cyst pressure to a serious degree and causes a large rupture risk.

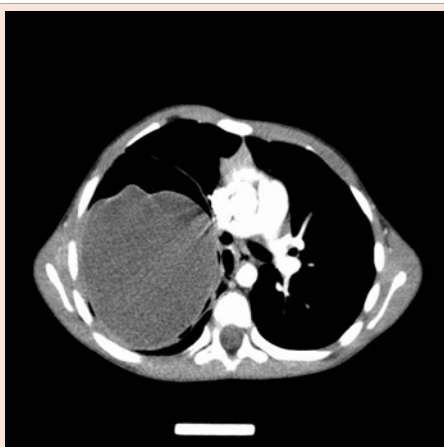

Figure 1: Giant hydatid cyst in the right lung.

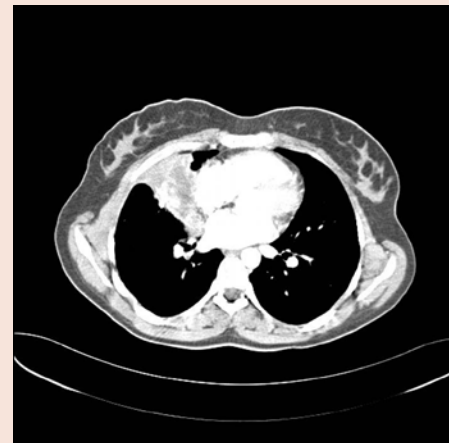


Figure 2: Atelectasis on the right lung upper lobe due to hydatid.

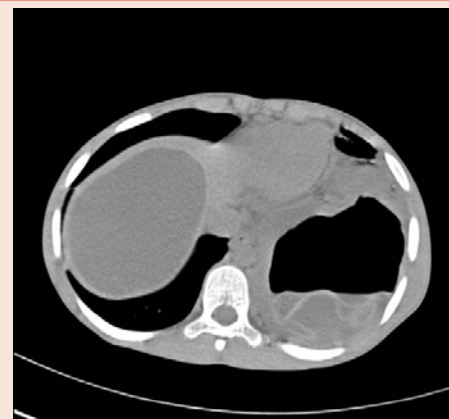

Figure 3: Intact on the right, perforated hydatid cyst on the left.

The complications in ruptured hydatid cysts are seen more frequently compared to intact cysts hydatidics [8]. Complications of a ruptured cyst can be ordered as: asphyxia (membrane and cyst fluid expectoration), hemoptysis, anaphylactic shock, respiratory failure, pneumonia, destroyed liver, bronchiectasis, pulmonary abscesses, empyema, pneumothorax, and aspergilloma in the cyst cavity (Figure 5). Additionally, a perforated hydatid cyst can cause extrapulmonary destruction in the sternum and ribs.

In particular, large ruptured cysts can result in asphyxia of cyst fluid or membrane fragments that fill the tracheobronchial system and result in sudden death [8].

In the current study, although 10.79% of the 176 cases of perforated hydatid cysts had cyst membrane expectoration, but none of them had asphyxia clinical course [12].

Hemoptysis is a complication frequently observed as a result of the rupture of intraparenchymal cysts. It is reported at a rate of 1.8-8% in different series [8]. In our two different studies, hemoptysis was detected in 42.7% cases and only 6 of them (1.45%) had massive hemoptysis [7,12].

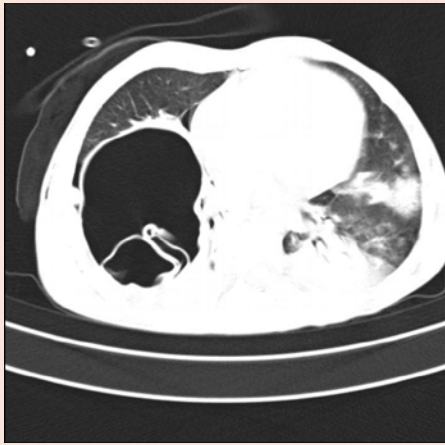


Figure 4: Perforated hydatid cyst on the right and undulant membrane appearance.

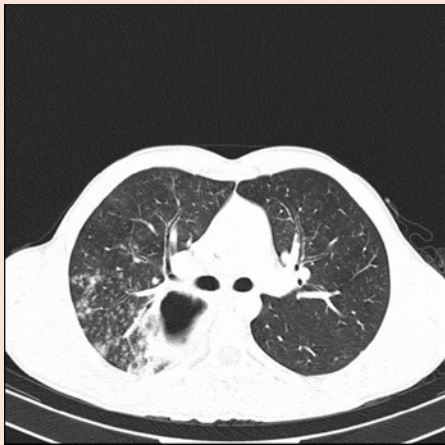

Figure 5: Perforated hydatid cyst on the right and pneumonic infiltrations on the peripheral parenchyma tissue.

Rupture is a predisposing factor for infection, which is the most serious complication. The frequency of this complication is reported between 30-90%. Infected hydatid cysts can show a thick and opacifying wall structure, similar to lung abscesses, and include air-liquid level and a pneumonic consolidation area can surround them [13]. When the cyst cavity is involved in the bronchial system, this prepares the environment for bacterial and fungal infections. The pneumonia in the peripheral parenchyma after an infection of the cyst cavity, bronchiectasis in the delayed cases and a destroyed lung are the pathologies encountered [8,10,11]. In the case that the cyst is infected, immune complex disease, glomerulonephritis, nephrotic syndrome, and secondary amyloidosis can develop [13].

In the current study, which included cases with perforated hydatid cyst, an infection clinical course consisting of lung abscesses, empyema, and pneumonia were detected in 40.9% of the cases [12].

Respiratory failure is a rare complication of hydatid cysts. The large cysts that depend on invasive parenchymal involvement caused

by *Echinococcus multilocularis* or *Echinococcus granulosus* and may lead to respiratory failure [14] (Figure 6).

If the cyst leaks without a serious rupture, recurrent urticaria or bronchospasm may develop as a symptom of hypersensitivity [14]. If the cyst ruptures and antigenic material spreads, this may lead to sudden and delayed reactions, and provoke allergies, eosinophilic pneumonia, and even anaphylaxis.

Pleural complications

Pleural involvement in hydatid disease is formed primarily with the hematogen or lymphatic route and direct larval infestation of the pleura or secondarily with the spread of cyst content throughout the pleura as a result of a rupture of an adjacent pulmonary or hepatic cyst [15].

Parenchymal hydatid cysts, ruptured or intact, can progress particularly with pleural effusion and with complications such as empyema, pneumothorax. On average 5-13% of the hydatid cyst patients may develop complications such as pleural effusion, pneumothorax, hydropneumothorax, tension pneumothorax, empyema, bronchopleural fistula, pleural thickening, trapped lung, and secondary pleural hydatid disease [6,8,15].

Pleural effusion formed in intact cysts frequently develops as parapneumonic effusion and liquid exudate [6] (Figure 7).

If there is no pleural adhesion in the rupture to pleura, the rupture will result in pneumothorax or a hydropneumothorax and in such cases, generally there are small bronchial fistula that are not large enough to discharge the content of the cyst.

If there is pleural adhesion, following to pachypleuritis, pleural thickening will occur and the pleura will be cultured [16]. As a result that the live scolex that is released from the ruptured pulmonary hidatic cyst is cultivated to the cavity, secondary pleural hydatid disease occurs [16].

In our series of 412 cases where surgical procedures were examined and in our series of 176 cases where the complications related to perforated hydatid cysts, the rate of pleural complication

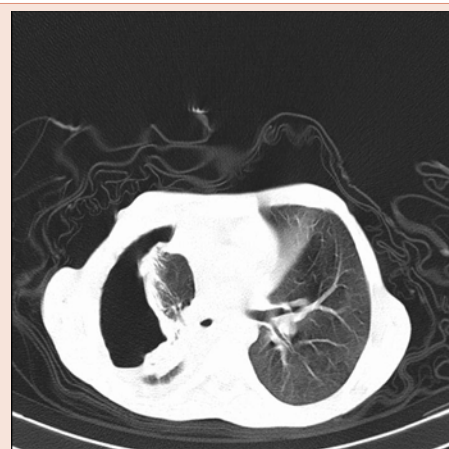

Figure 6: Collapsed lung due to the giant perforated hydatid cyst on the right.

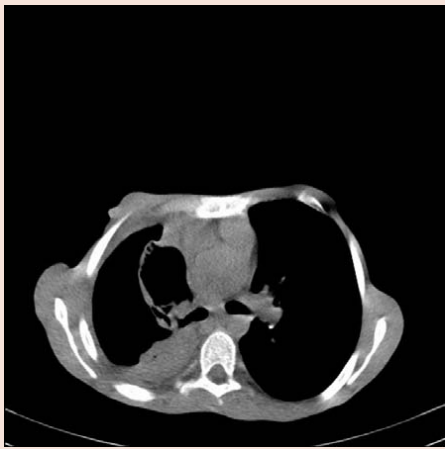

Figure 7: Perforated hydatid cyst and pleural effusion on the right.

was 26.94% [7,12]. 22.77% of 176 cases with perforated hydatid cyst were detected to have pneumothorax. Two of these (1.13%) were tension pneumothorax. Pleural effusion in 36 (20.45%) cases, empyema in 35 (19.88%) cases, and pleural thickening in 17 (9.65%) cases were detected [12].

Cardiac complications

The cysts in the cardiac area are seen at a rate of 0.02-2% [15,17]. Since the vascular ground is richer, it is seen in the left ventricular wall most frequently, and may be seen in the right ventricle and other locations around the heart. The accession of *Echinococcus* embryo to the left chamber of the heart occurs through coronary circulation and to the right chamber through venous return [16]. There are two potential mechanisms through which the embryo can access the coronary circulation.

Transmission is realized through patent foramen ovale or pulmonary circulation, with the scolexes passing from hepatic system to the right atrium or to the pulmonary veins through tears in the lung cyst [18].

The embryo reaches full maturity within one to five years after it reaches the heart. In the cyst, adventitial pericyst layer occurs as myocardial reaction [18]. The cysts in the right chamber of the heart tend to grow as intracavitary and subendocardial, the left heart cysts tend to grow subepicardial.

The complications are reported to be associated with the cardiac cysts: rupture, pulmonary and systemic embolism, heart block, cardiac valve obstruction, congestive heart failure, pericarditis, cardiac tamponade, acute myocardial infarction, anaphylaxis, and pulmonary hypertension [6,18].

In cardiac hydatid cysts with an interventricular septum location, atrioventricular block, syncope attacks, and apnea may develop depending on compression in the cardiac nerve conduction paths [19]. The cysts in the right ventricle are ruptured more frequently and they may lead to pulmonary embolism, anaphylaxis, and sudden

death. As a result of rupture to the pericardial cavity, effusion, and cardiac tamponade may develop. The heart can be affected secondarily with direct contact with hepatic and pulmonary cysts.

Although it is rare, the complications such as pulmonary artery stenosis and compression have been reported for the cysts with central location [20]. The cysts that create pressure on coronary arteries may lead to myocardial infarction [15,17].

Mediastinal complications

Mediastinal hydatid cyst is seen at a rate of 0.1% as primer [21]. This parasite may reach the mediastinal region through a branch of the thoracic aorta or lymph nodes [21]. Many mediastinal cysts settle on the paravertebral sulcus. It is rare that cysts with a paravertebral location may expand to the spinal duct. These cysts, which are called pince-nez cysts in the literature, form when the cyst with a paravertebral location reaches the opposite paravertebral area through the front of the vertebra from the back of the aorta and esophagus [21]. The visceral mediastinum is a rare localization for hydatid cysts.

Mediastinal hydatid cysts may be solitary or multiple. Symptoms and the complications depend on the size, localization of the cyst, and involvement of the peripheral structures [13]. Furthermore, they erode some main vascular structures, and pressure and associated complications may be seen. Mediastinal cysts frequently lead to the compression of mediastinal shift, cardiac and main vascular structures and also rarely lead to Horner's syndrome, thoracic outlet syndrome, diaphragmatic eventrations as a result of phrenic nerve failure, respiratory disorder after tracheal compression, and failure to thrive due to esophagus pressure [21].

In the current study, there were six (1.45%) hydatid cyst cases that were all intact, consisting of two (0.48%) visceral, and four (0.97%) settled in the posterior mediastinum. The cysts located in the visceral mediastinum had small diameters and in the two cases with posterior mediastinum locations, there was esophagus pressure [7].

Thorax wall complications

Hydatid cyst cases with chest wall locations are very rarely observed. The focus may be soft tissue, sternum or rib in the involvement of chest wall. Bone involvement in all hydatid cysts are seen between 0.9% and 2% [22].

Hydatid disease in the chest wall muscular structure occurs at a rate of 0.5-1% of all *Echinococcus* infections and generally occurs with propagation during surgery of the lesion in the liver and lungs [22].

Infection is generally removed during childhood; however, since the incubation time is longer than ten years, clinical appearance may be delayed until adulthood [22]. Direct implementation of the embryo through an infected dog bite and spread to the systemic circulation from the bowels and then passing through two important strainers (the liver and lung) and reaching to the muscle are the thoughts set forth in the related pathogenesis regarding primer skeleton muscle of hydatid cyst localization [22]. Hydatid cysts located in the thoracic wall may lead to muscle and bone destruction [6]. Pathological

changes caused by the hydatid cyst made to the thoracic wall radiologically imitate tumors of the thoracic wall [6].

In our clinic, a 31-year-old female patient was diagnosed with hydatid cyst with the size of 15x23 cm in the left posterolateral hemithorax, latissimus dorsi muscle [23]. In a case without infected dog bite story and hydatid cyst in the lung and liver, it was concluded that the cyst settled in the skeletal muscles, accessing the circulatory system through the bowels.

Settlement in the thoracic aperture and complications

The most frequent complications of the cysts that settle in the thoracic aperture are Vena Cava Superior syndrome and Horner's Syndrome, hoarseness after the Laryngeal nerve is invaded, Thoracic Outlet Syndrome, Subclavian artery pressure [6,24].

Respiratory system complications of the hydatid cysts in the liver

Hydatid cysts frequently settle in the right lobe of the liver and are generally solitary. They can lead to hydatid cysts in the lung or bronchobiliary fistula by accessing the bronchial tree through transdiaphragmatic transmission. Dome cysts in the liver that have become excessively large erode the diaphragm muscles and perforate the thorax.

The complications with diaphragmatic involvement of the liver cysts and intrathoracic propagation are reported at a rate of 0.6-16% [25]. These complications, many of which are seen in the cysts located in the liver dome can generally originate from factors including spontaneous, traumatic, and intraabdominal pressure increases. The pressure gradient between the thorax and abdomen cavity, diaphragmatic ischemia secondary to compression, inflammation in the cyst membrane, and the chemical effect of the gallbladder on the diaphragm are the other predisposing factors [25].

If the liver dome cysts become a perforated thorax, they may lead to pleural effusion, empyema, or parenchymal destruction. The opening of the liver hydatid cyst to the pleural cavity or bronchus is the cause of high mortality (9-43%) and morbidity [26]. In our series of 27 cases in which we examined liver dome cysts together with the lung, it was determined that 11 (40.74%) cysts in the lung were perforated and all the cysts in the liver were intact. All of these cases were operated on with thoracophrenotomy [27].

When the cyst crosses the diaphragm, it may rupture in the pleural cavity, intrathoracic large veins, pericardium, and the pulmonary parenchyma if there is adhesion between the diaphragm and lungs [25,26]. The gallbladder has a corrosive effect on the lungs and pleural area. An indication of the presence of gallbladder in the pleural liquid and with the analysis of biloptysis and bilirubin levels is pathognomonic for the fistula [25,26]. In the bronchobiliary fistula where the mortality is already high, the surgical treatment must be considered only when no response is given with conservative approaches [26].

Systemic complications

In the hydatid cyst cases, anaphylaxis and shock are life threatening complications that can be seen after cyst perforation [28].

When the cyst leaks without serious rupture, recurrent urticarial or bronchospasm may appear as a symptom of hypersensitivity. This situation that the allergic proteins caused in the cyst may create a simple allergic reaction in a short time during which the symptoms such as chest pain, itching, urticarial, flushing appear and also may lead to shock status [28].

In our series in which we examined perforated hydatid cysts, allergic complications were detected in 14 cases (7.95%), urticaria and erythema in six (3.40%) cases, and asthma and bronchial provocation in three (1.70%) cases were identified [12].

When the cyst ruptures, results ranging from anaphylactic shock to death may appear [28]. After the intraoperative cyst is drained into the bronchial system or pour into the blood circulation for a patient with stable progress under general anesthesia, if low blood pressure or shock are observed, within minutes the reaction must be suspected [28].

Anaphylaxis is an unwanted hypersensitivity reaction of which the clinic status may be very serious. This may result in death due to vascular collapse and obstruction of the airway [29].

It should be kept in mind that allergic reactions may be observed, depending on the cyst rupture after anthelmintic hydatid cyst treatment or percutaneous aspiration [28]. In the liver hydatid cyst, allergic reactions depending on spontaneous cyst rupture are reported but the case of lung hydatid cyst that appears with anaphylaxis is very rare [28].

Conclusion

Under the conditions in Turkey, not only the doctors of general surgery or thoracic surgery, but also the doctors from almost all branches encounter hydatid cysts once in their careers. Hydatid cysts present with many different clinical findings because of the potential of the involvement of various organs and the complications that may develop. Complicated hydatid cysts may clinically imitate many diseases and radio logically, the problems may occur in the diagnosis, long hospitalization time, and high hospital costs may appear. Therefore, the complications that may develop during the progression of hydatid cyst and the clinical findings depending on these complications must be known.

References

1. Güngör Ç (2008) Pulmoner Echinococcosis: Echinococcus Morphology, Biology and Epidemiology. *Türkiye Klinikleri J Thor Surg Special Topics* 1: 1-7.
2. Yazar S (2005) Cystic echinococcosis in Kayseri during the last six years. *Türkiye Parazit Derg* 29: 241-243.
3. Çiledağ A, Kaya A. Clinic of Hydatid Cyst Disease. *Türkiye Klinikleri J Thor Surg Special Topics* 1: 8-10.
4. Halezeroğlu S, Çelik M, Uysal A, Ürek Ş, Şenol C, et al. (1995) Giant hydatid cyst of the lung. *GKD Cer Derg* 3:75-77.
5. Arroud M, Afifi MA, El Ghazi K, Nejari C, Bouabdallah Y (2009) Lung hydatid cysts in children: comparison study between giant and non-giant cysts. *Pediatr Surg Int* 25: 37-40.
6. Yekeler E, Karaoğlanoğlu N (2012) Akciğerin Parasitic Diseases of the Lung:

- Hydatid Cyst Complications. *Türkiye Klinikleri J Thor Surg Special Topics* 5: 157-164.
7. Sayır F, Çobanoğlu U, Şehitoğulları A, Bilici S (2012) Our eight-year surgical experience in patients with pulmonary cyst hydatid. *Int J Clin Exp Med* 5: 64-71.
 8. Kılıç D, Fındıkcıoğlu A, Bilen A, Koç Z, Hatipoğlu A (2007) Management of complicated hydatid cyst of the thorax. *ANZ J Surg* 77: 752-757.
 9. Çobanoğlu U, Sayır F, Mergan D (2011) Diagnostic Dilemma: Analysis of 11 Cases of Hydatid Disease. *Türkiye Parazitoloj Derg* 35: 164-168.
 10. Fındıkcıoğlu A, Kılıç D, Canpolat T, Hatipoğlu A (2010) Necessity of lung resection in neglected cases of pulmonary hydatidosis. *Ann Thorac Cardiovasc Surg* 16: 187-189.
 11. Balcı AE, Eren N, Eren Ş, Ülkü R (2002) Ruptured hydatid cysts of the lung in children: Clinical review and results of surgery. *Ann Thorac Surg* 74: 889-892.
 12. Çobanoglu U, Sayır F, Şehitoğlu A, Bilici S, Melek M (2011) Therapeutic strategies for complications secondary to hydatid cyst rupture. *Int J Clin Exp Med* 4: 220-226.
 13. García MB, Lledías JP, Pérez IG, Tirado VV, Pardo LF, et al. (2010) Primary superinfection of hydatid cyst clinical setting and microbiology in 37 cases. *Am J Trop Med Hyg* 82: 376-378.
 14. Hijazi MH, Al-Ansari MA (2007) Pulmonary hydatid cyst in a pregnant patient causing acute respiratory failure. *Ann Thorac Med* 2: 66-68.
 15. Arıbas OK, Kanat F, Görmüş N, Türk E (2002) Pleural complications of hydatid disease. *J Thorac Cardiovasc Surg* 123: 492-497.
 16. Skerrett Sj, Plorde jj (1992) Parasitic infections of the pleural space. *Semin Respir Crit Care Med* 13: 242-258.
 17. Demircan A, Keles A, Kahveci FO, Tulmac M, Ozsarac M (2010) Cardiac tamponade via a fistula to the pericardium from a hydatid cyst: case report and review of the literature. *J Emerg Med* 38: 582-586.
 18. Laglera S, Garcia-Enguita MA, Martinez-Guiterrez F, Guiterrez-Rodriguez A, Urieta A, et al. (1997) A case of cardiac hydatidosis. *Br J Anaesth* 79: 671-673.
 19. Paflaoğlu I, Doğan R, Paflaoğlu E, Tokgözoğlu L (1994) Surgical treatment of giant hydatid cyst of the left ventricle and diagnostic value of magnetic resonance imaging. *Cardiovasc Surg* 2: 114-116.
 20. Merchante A, Colomé JA, Díaz Fernández AJ, Gallardo J, Sáiz F (1974) Acquired pulmonary stenosis. A case of pulmonary artery compression caused by hydatidic cyst. *Rev Clin Esp* 135: 289-293.
 21. Rakower J, Milwidsky H (1960) Primary Mediastinal Echinococcosis. *Am J Med* 29: 73-83.
 22. Melis M, Marongiu L, Scintu F, Pisano M, Capra F, et al. (2002) Primary hydatid cysts of psoas muscle. *ANZJ Surg* 72: 443-445.
 23. Çobanoğlu U (2009) Cyst in the muscle. *Solunum* 11: 137-139.
 24. Ziyade S, Soysal O, Uğurlucan M, Yediyıldız S (2009) Pancoast hydatid cyst leading to horner syndrome: thoracic hydatidosis. *Heart Lung Circ* 18: 363-364.
 25. Kabiri EH, EL Maslout A, Benosman A (2001) Thoracic rupture of hepatic hydatidosis (123 cases). *Ann Thorac Surg* 72: 1883-1886.
 26. Rando K, Harguindeguy M, Zunini G (2008) Echinococcal disease with bronchobiliary fistula. *Can J Surg* 51: 117-118.
 27. Sayır F, Çobanoğlu U, Şehitoğulları A, Sertoğullarından B (2012) Our therapeutic strategies for right lung and liver dome hydatid cysts. *Tıp Araştırmaları Derg* 10: 54-58.
 28. Salmones MG, Gil R, Rabanal JM (1997) Anaphylactic shock during pulmonary hydatid surgery: apropos a case. *Arch Bronconeumol* 33: 479-480.
 29. Karaman Ö, Köse S (2003) Anaphylaxis. *Klinik Pediatri* 2: 89-97.