

Maria Grazia Bongiorno, Giovanni Coluccia*, Luca Segreti, Luca Paperini and Ezio Soldati

Second Cardiology Division, Cardiothoracic and Vascular Department, University Hospital, Pisa, Italy

Dates: Received: 24 April, 2015; Accepted: 26 May, 2015; Published: 28 May, 2015

***Corresponding author:** Giovanni Coluccia, MD, Second Cardiology Division, University Hospital of Pisa, Via Paradisa, 2 - 56100 PISA Italy, Tel: +39050993043; Fax: +39050992352; E-mail: messapus@gmail.com

www.peertechz.com

ISSN: 2455-5452

Keywords: Lead extraction; ICD lead; Percutaneous repositioning; Displaced lead; Pigtail catheter

Case Report

Effective Percutaneous Repositioning of an Active Fixation ICD Lead

Abstract

We report a case of effective trans catheter repositioning of an ICD lead that was displaced during a trans venous extraction procedure of another malfunctioning ICD lead. This original technique was effective also in screwing-in the active fixation tip of the lead. Skilled operators could take into account this technique to avoid the re-opening of the device pocket, when dealing with specific situations at high risk of infection.

ventricular ejection fraction. No other relevant comorbidities were known.

The patient presented to our attention with two leads: the abandoned dual-coil lead and the single-coil malfunctioning lead (Kainox RV-S 75, Biotronik, Berlin, Germany), that was targeted for TLE (Figure 1A). The indication for TLE raised after evidence of significantly decreased shock impedance, from the chronic values around 65 Ohm, to 29 Ohm. Lead dwelling time was twelve years and a procedure of TLE with concomitant new system implantation was planned under general anesthesia.

Fibrous adherences in the venous tree were very robust. Single-sheath mechanical dilatation from left subclavian venous entry side in superior vena cava, right atrium (RA) and ventricle (RV) was really challenging. During dilatation, the lead was broken in several points and its remaining extravascular portion was minimal. We decided to cross over to an internal transjugular approach. A deflectable diagnostic catheter was advanced from the left femoral vein and used to grasp the lead in the RA; at this point, the lead was completely intravascular and was then exteriorized from the right internal jugular vein, using two Lasso catheters to catch its externalized cables [1,2].

Abbreviations

TLE: Transvenous Lead Extraction; ICD: Implantable Cardioverter Defibrillator; RA: Right Atrium; RV: Right Ventricle

Case Presentation

A 74-years-old male patient was referred to our Institution for transvenous extraction (TLE) of a malfunctioning defibrillator (ICD) lead. Patient's clinical history reported a previous episode of aborted sudden cardiac death, occurred two years after an anterior acute myocardial infarction and a subsequent surgical revascularization. After resuscitation, the patient underwent coronary angiography, which showed no possibility of further percutaneous or surgical revascularization. A single-chamber ICD system was implanted. Three years later, the occurrence of inappropriate shocks revealed a lead malfunction, unsuccessfully treated with extraction: the lead was abandoned and a new one was implanted. In the follow-up, the patient presented appropriate ICD shocks, despite a 50% left

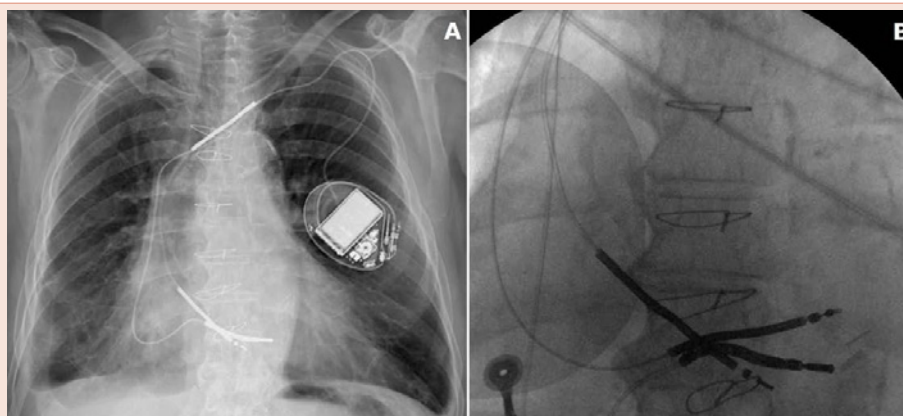


Figure 1: Panel A: chest X-ray at admission, showing the abandoned dual coil lead and the malfunctioning single-coil ICD lead. Panel B: the new active fixation ICD lead is implanted.

Given the long duration of the procedure and the infection risks, we decided to perform the new system implantation at this point, using the same subclavian venous access and left prepectoral pocket. A new single-coil ICD lead with active fixation mechanism was implanted; its tip was screwed-in to the distal portion of the interventricular septum (Figure 1B). The new lead was then connected to a new single-chamber ICD and the pocket was closed and sutured. Then we proceeded to complete the TLE procedure.

The mechanical dilatation from right internal jugular vein was effective in dissecting the binding sites in the RA, tricuspid valve and RV and the lead was removed. During the procedure, the just-implanted active fixation ICD lead was displaced in the RV outflow tract (Figure 2A).

To avoid the re-opening of the pocket, we tried to reposition the lead using a novel approach, never previously reported in similar cases. A 145°-angled pigtail catheter filled with saline was advanced

from the left femoral vein to the RV and carefully driven to envelop the distal portion of the lead (Figure 2B). Once wrapped the lead at the coil level, it was kept in gentle pushing towards the basal portion of the interventricular septum. Some clockwise rotations of the pigtail catheter were performed and transmitted to the lead tip, which was then screwed-in to the basal septum in this way. At this point, the pigtail catheter was gently released and pulled back. The reached position of the lead tip proved to be stable and electrical parameters of the lead were good. Lead position remained unchanged also after the ICD testing and was confirmed at discharge chest X-ray. At six-month follow-up visit, electrical parameters of the lead are still good, the patient is well and at X-ray (Figure 3) the lead tip is stable in the position reached after percutaneous repositioning.

Discussion

The displacement of a permanent lead which is not targeted for extraction is one of the possible complications of a TLE procedure.

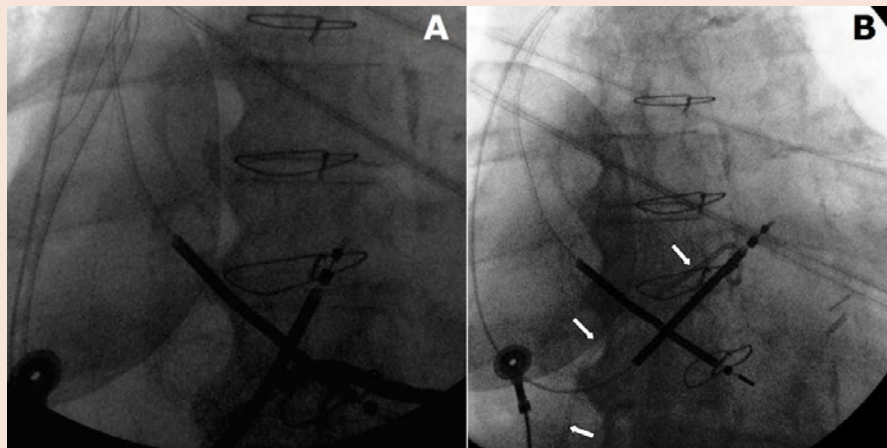


Figure 2: Panel A: during the extraction procedure, the new ICD lead is displaced into the right ventricular outflow tract. Panel B: a 145°-angled pigtail catheter (arrows) is advanced from the femoral vein to the right ventricle to percutaneously reposition the displaced lead.

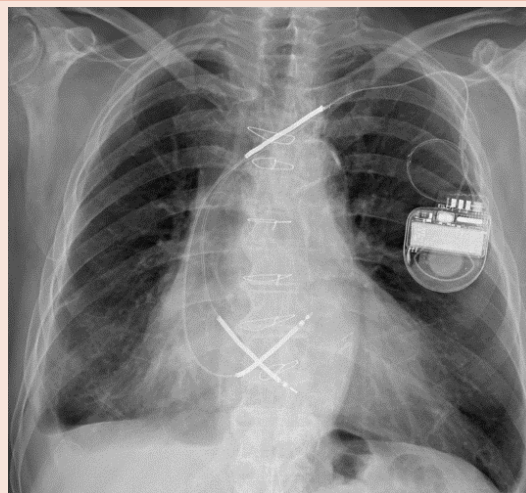


Figure 3: At six-months X-ray, the lead tip is stable in the position reached after percutaneous repositioning.

The repositioning of the lead requires opening of the device pocket to work with the proximal end of the lead, trying to put its tip in the correct position.

Few reports have been described in the literature, regarding percutaneous techniques to avoid the re-opening of the pocket, in cases of displaced leads. These cases were mostly about atrial leads, which were repositioned using a trans-femoral approach and deflectable catheters [3], diagnostic catheters and guidewires [4-7] or even modified urological tools [8].

In our case, the described transcatheter approach was used to reposition an active fixation ICD lead, which was also screwed-in to the interventricular septum. The reached position was proved to be good in terms of electrical parameters and stability, also after the mechanical stress due to the ICD testing and at six-month follow-up X-ray. The long duration of the extraction procedure forced us to perform the new ICD implantation before completing extraction, to avoid the infectious risks of keeping the pocket open for too long time. Once completed the extraction, we considered re-opening the pocket to reposition the displaced lead too much risky in terms of infection, and so we tried to solve the problem percutaneously.

We believe that this way of repositioning of a displaced lead cannot be simply considered as an alternative to the traditional way (that remains the gold standard), but it could be taken into account

by skilled operators when dealing with specific situations at high risk of infection.

References

1. Bongiorni MG (2011) Transvenous lead extraction. From simple traction to internal transjugular approach. Milan: Springer Verlag Italia 83-96.
2. Bongiorni MG, Segreti L, Di Cori A, Zucchelli G, Viani S, et al. (2014) Safety and efficacy of internal transjugular approach for transvenous extraction of implantable cardioverter defibrillator leads. *Europace* 16: 1356-1362.
3. Yoshida N, Yamada T, McElderry HT (2014) Successful percutaneous repositioning of a dislodged pacemaker lead. *Europace* 16: 148.
4. Kursaklioglu H, Barcin C, Iyisoy A, Kose S, Isik E (2004) Percutaneous transcatheter repositioning of displaced permanent pacemaker atrial lead with a simple system. *Int J Cardiovasc Intervent* 6: 88-90.
5. Favale S, Nacci F (1999) Percutaneous transcatheter repositioning of displaced permanent pacemaker lead. *Pacing Clin Electrophysiol* 22: 1817-1819.
6. Morris DC, Scott IR, Jamieson WR (1989) Pacemaker electrode repositioning using the loop-snare technique. *Pacing Clin Electrophysiol* 12: 996-999.
7. Sochman J, Lefflerová K, Vrbská J, Kovác J (1995) Catheter aided repositioning of a displaced permanent pacemaker lead. *Pacing Clin Electrophysiol* 18: 1964-1965.
8. Sharif AY, Davoodi G, Saeed AK, Sadeghian S (2007) New technique: repositioning of dislodged a trial pacing lead with a specially designed urological basket. *Europace* 9:105-107.