

Clinical Image

Herpes Zoster Masquerading as Acute Coronary Syndrome

Ishrat Hussain Dar*

Department of Medicine, Govt. Medical College Srinagar, J & K, 190010, India

*Corresponding author: Ishrat Hussain Dar, MD, Assistant Professor, Department of Medicine, Govt. Medical College Srinagar, J & K India – 190010, Tel: +91 9419042320; E-mail: drishratdar@gmail.com

Dates: Received: 10 August, 2015; Accepted: 29 October, 2015; Published: 30 October, 2015

www.peertechz.com

ISSN: 2455-5452

Clinical Image

A 65 year old male presented to the causality department of our hospital with one day history of burning chest pain in the right upper half of the chest radiating to the right axilla & the left precordial region associated with diaphoresis. No history of fever, cough or rash was evident. Vitals were normal. An X ray chest done was normal and ECG showed RBBB (Figure 1). A Troponin T (qualitative) test along with cardiac enzymes was done in view of possible acute coronary syndrome which were noncontributory as well. The patient was given symptomatic treatment by the resident on duty but on the second day he returned back with a vesicular eruption in the upper part of the trunk on the right side which extended to the axilla and the right mammary area (Figures 2a, b). A diagnosis of Acute Herpes Zoster involving the right T 2 & T 3 dermatomes was made & the

patient was started on Acyclovir 800 mg five times daily along with Codiene & Acetaminophen for relief of pain and Calamine lotion locally. The same was continued for 10 days which resulted in clearing of the eruption (Figure 3) with relief from pain. Herpes zoster or Shingles is an acute vesicular eruption due to varicella zoster virus. It usually occurs in adults and pain precedes the eruption by 48 hours or more and the lesions consist of grouped, tense, deep seated vesicles distributed unilaterally along a dermatome commonly on the trunk and the face. A generalized disease is commonly associated with an immunosuppressive disorder like Hodgkin's disease or HIV infection. A subsequent evaluation and review of old records revealed RBBB in old ECG's. The case is highlighted to impress upon the resident staff to undertake a thorough general physical examination of patients along with review of old records to minimize the possibilities of making an erroneous diagnosis.

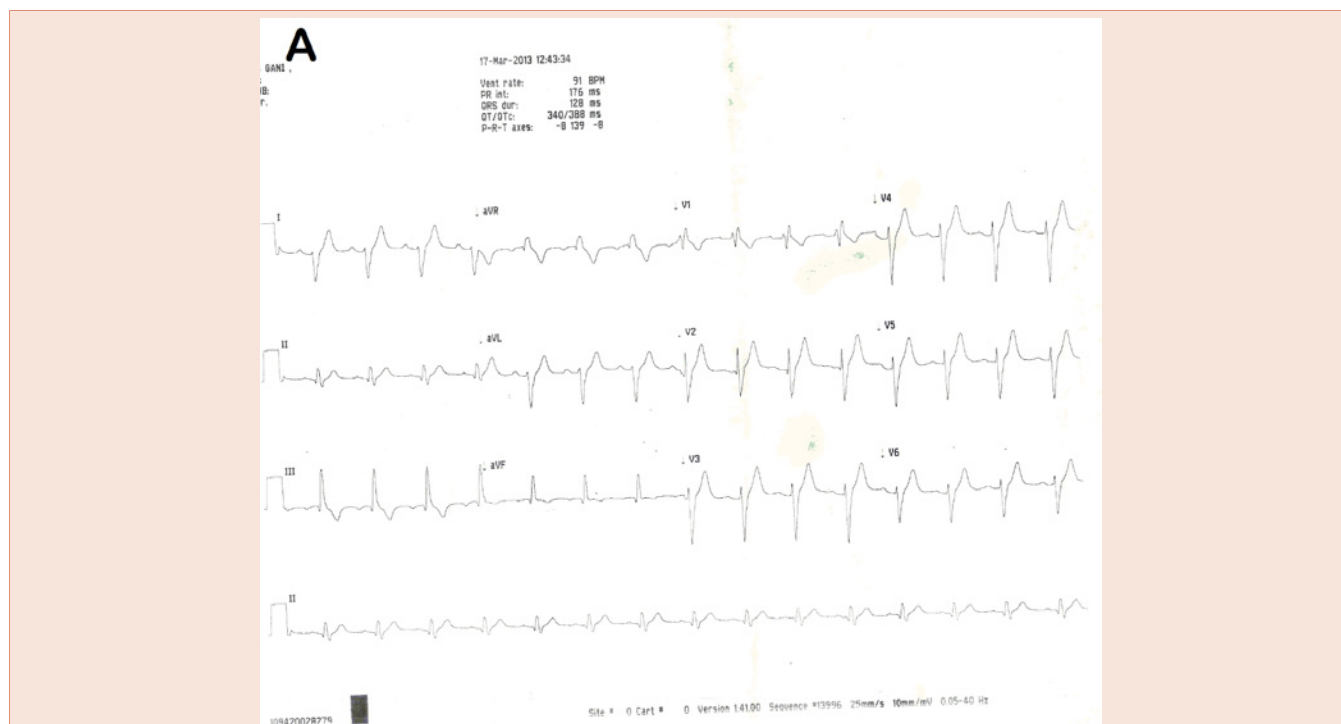


Figure 1:

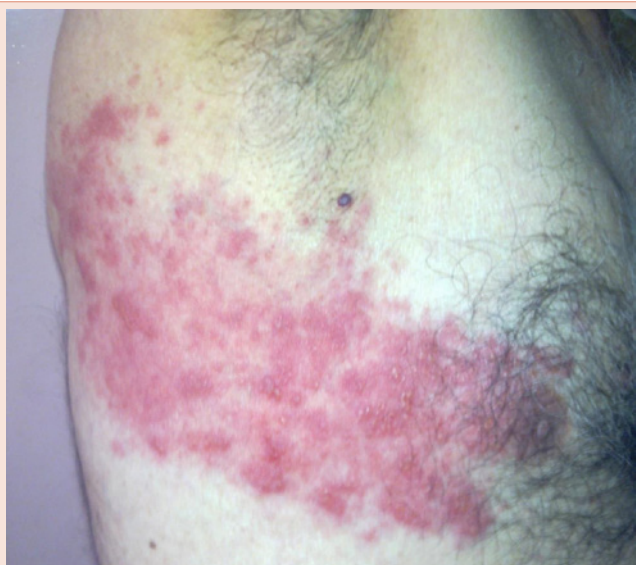

Figure 2a: Before treatment.

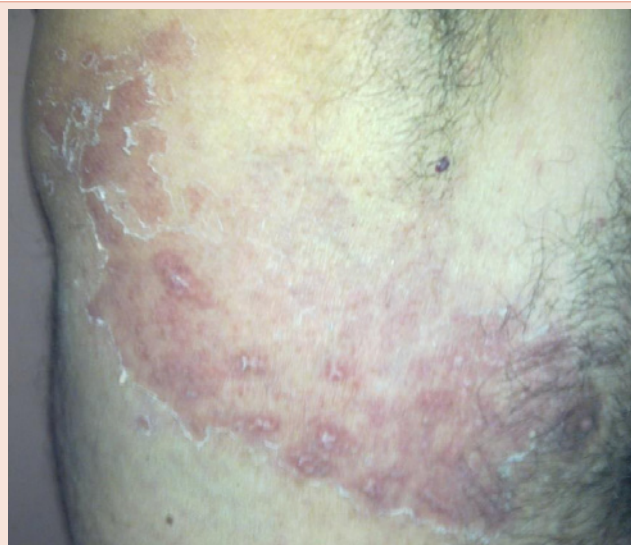

Figure 3: After treatment.

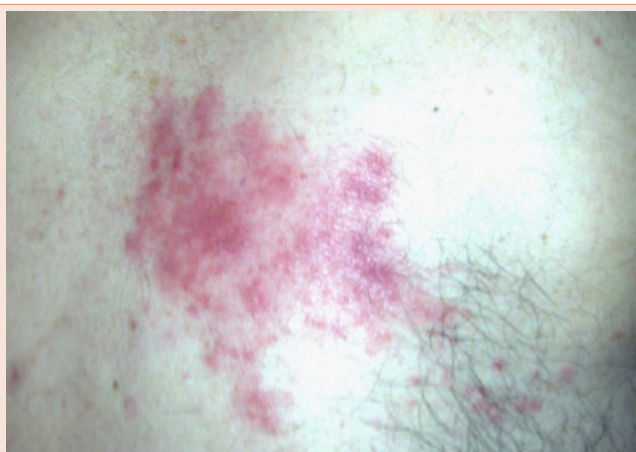


Figure 2b: Before treatment.

Copyright: © 2015 Dar IH. This is an open-access article distributed under the terms of the Creative Commons Attribution License, which permits unrestricted use, distribution, and reproduction in any medium, provided the original author and source are credited.

Citation: Dar IH (2015) Herpes Zoster Masquerading as Acute Coronary Syndrome. *Int J Vasc Surg Med* 1(1): 012-013. DOI: 10.17352/2455-5452.000005