

Roberto Ceravolo<sup>1</sup>, Marco Vatrano<sup>1</sup>,  
Giuseppe Dattilo<sup>2</sup>, Alessandro Ferraro<sup>1</sup>,  
Vincenzo Antonio Cicone<sup>1</sup> and Egidio  
Imbalzano<sup>2\*</sup>

<sup>1</sup>UTIC and Cardiology, Hospital "Pugliese-Ciaccio"  
of Catanzaro, Italy

<sup>2</sup>Department of Clinical and Experimental Medicine,  
University of Messina, Italy

**Dates:** Received: August 22, 2014; Accepted:  
September 11, 2014; Published: September 13,  
2014

**\*Corresponding author:** Egidio Imbalzano, MD,  
Department of Clinical and Experimental Medicine,  
Policlinic University of Messina, Via Consolare Valeria  
n.1, 98125 Messina, Italy, Tel: +393392894665;  
E-mail: eimbalzano@unime.it

[www.peertechz.com](http://www.peertechz.com)

**Keywords:** Spontaneous coronary artery dissection;  
Cocaine-related acute coronary syndromes; Coronary  
angiography; Everolimus-eluting bioresorbable  
vascular scaffold stent

**ISSN:** 2455-2976

## Case Report

# Spontaneous Coronary Artery Dissection and Implantation of Absorb Bioresorbable Drug-Eluting Stent in Cocaine-Related Acute Coronary Syndrome

## Abstract

The spontaneous dissection of the coronary arteries (SCAD) is rare and few data are available in the worldwide literature. Several diseases and conditions have been associated with SCAD, such as atherosclerosis, connective tissue disorders and the peripartum episode. Cocaine addiction is one of causes of the disease in young patients. In this paper we present a case report of a patient with a acute coronary syndrome who had a history of recent cocaine abuse. The coronary angiography showed spasm and spontaneous dissection of the left anterior descending artery with a slow coronary flow. Based on the clinical and angiographic characteristics of the patient, we decided to perform a coronary angioplasty with bioresorbable vascular scaffold stent placement.

## Introduction

Spontaneous coronary artery dissection (SCAD) is a rare entity leading to acute coronary syndrome (ACS). Some of these reported cases have occurred in young patients who abuse cocaine that may produce coronary vasospasm, thrombotic coronary occlusion, and marked systemic hypertension. There is no standardized therapeutic management for patients with SCAD, as there are no studies comparing different strategy due to the small number of cases reported in the literature. To the best of our knowledge, no data are available regarding the use of bioresorbable vascular scaffold (BVS) stent in patients with ACS due to coronary artery dissection secondary to cocaine abuse.

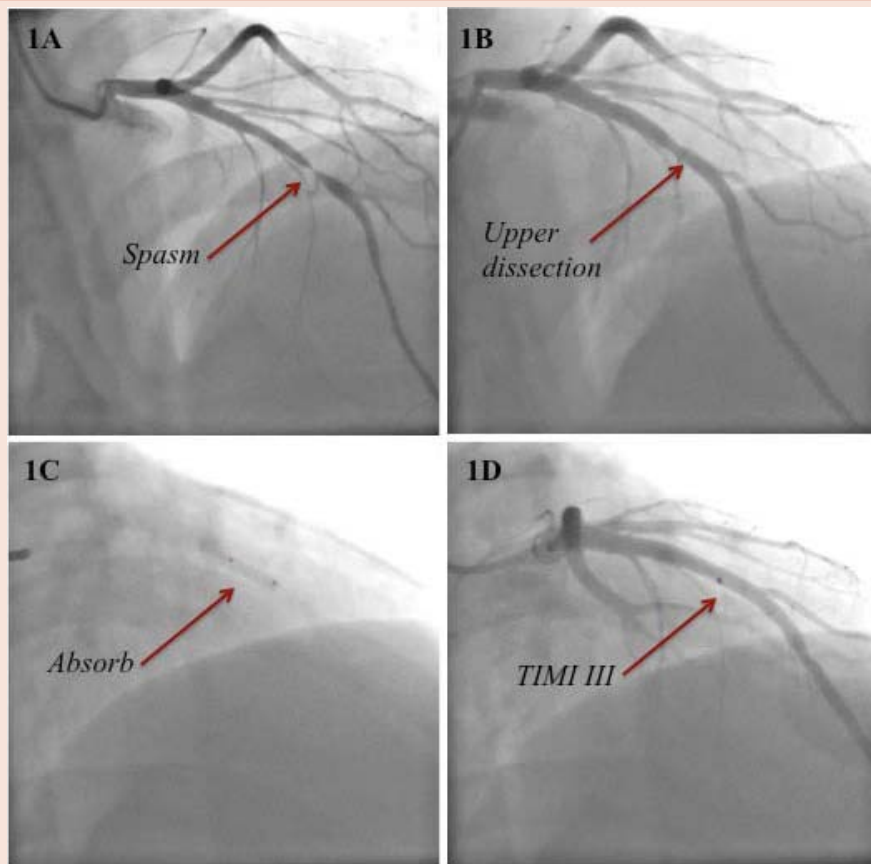
## Case History

A 27-year-old male presented to the emergency department with residual chest pain began two days before. He was current smoker with family history of coronary artery disease. In addition, he reported fever in the previous week. His electrocardiogram revealed negative precordial T-wave and echocardiogram showed a hypokinetic anterior wall with reduced left ventricular function. High-sensitive troponin-T (hs Tn-T) and Creatine Kinase (CK) levels were increased. Due to patient's clinical status and to the instrumental and laboratory findings he was referred to our cardiology department. At admission, the patient was hemodynamically stable (heart rate: 70 bpm; blood pressure: 130/80 mm Hg) and fully asymptomatic. Physical examination was within normal parameters. Considered clinical presentation suggesting acute myocarditis, it was decided to manage the patient conservatively. However, after repeated requests, patient reported to make use of cocaine since two weeks and in view

of possible drug-induced vasospasm related ACS; it was decided to perform invasive evaluation with cardiac catheterization. Coronary angiography, on the second day, revealed a incompletely reversible spasm, after intracoronary administration of 100 micrograms of nitroglycerin [1], in the mid segment of left anterior descending coronary artery (Figures 1A and 1B) with normal left circumflex and right coronary arteries. In addition, during the diagnostic procedure, without obvious iatrogenic causes such as a guide wire, it became evident a short and linear dissection with slow-flow at the same site. Given the clear morphologic characteristics of the coronary dissection and the related persistence of the spasm, it was decided to perform an angio-guided stenting with the implantation of an everolimus-eluting bioresorbable vascular scaffold stent (3.5 x 18 mm – Absorb<sup>®</sup>BVS, Abbott Laboratories Co., Abbott Park, IL, USA) with optimal result (Figures 1C and 1D). During the following five days the patient evolved without complications and he was discharged with dual platelet aggregation inhibitors, angiotensin converting enzyme inhibitors, calcium channel blockers and statin. He is currently at follow-up at the outpatient clinic and on rehab for his addiction to cocaine.

## Discussion

SCAD is a rare but recognized cause of non-atherosclerotic ACS, with a prevalence ranging from 0.1% to 1.1% [2]. It is more common in women (3:1) [3], specially during pregnancy and in the postpartum period [4]. SCAD is also associated with sleep deprivation [5], intense physical activity [6], connective tissue diseases [7,8], pharmacological agents [9] and toxic agents, such as cocaine [10]. The first case of cocaine-induced SCAD was described in 1994 [11]. The coronary dissection, and the ischemia of the myocardial region supplied by the



**Figure 1:** Coronary angiography revealed a incompletely reversible spasm of the mid segment of left anterior descending (LAD) coronary artery (figures 1A and 1B) with normal left circumflex and right coronary arteries. In addition it became evident a linear dissection with slow-flow at the same site. Taking account the vessel size and the age of the patient, it was decided to treat the lesion with the implantation of an everolimus-eluting bioresorbable vascular scaffold stent (figures 1C and 1D) with optimal result.

injured artery, has been attributed to the action of cocaine through a variety of pathophysiologic mechanisms. Even small doses of cocaine have been associated with vasoconstriction of coronary arteries [12], above all in patients with preexisting coronary artery disease [13] and in young men who also smoke cigarettes [14]. Cocaine-induced vasoconstriction is often secondary to the block of the reuptake of noradrenaline and dopamine with a powerful sympathetic response due to sustained alpha- and beta-adrenergic stimulation. In addition, cocaine has been shown to increase levels of endothelin-1 [15] and to decrease production of nitric oxide [16]. Cocaine may enhance platelet activation with potential intra-coronary thrombosis [17]. Thus, a combination of sympathetic over-activity, vasospasm and thrombosis, with the background of a possible atherosclerotic segment of arterial wall, may be responsible for an abrupt shear wall stress leading to the formation of an intimal tear and the subsequent dissection of the coronary artery. Due to the lack of specific evidence, management should be individualized according to the patient's clinical and angiographic characteristics, such as the severity of spasm, the site and extent of dissection and the concomitant presence of atherosclerosis. Therefore, coronary angiography is the primary tool for diagnosis of SCAD. Intracoronary imaging techniques such as intravascular ultrasound (IVUS) and optical coherence tomography

(OCT), have enabled a more detailed morphological information of SCAD [18]. We did not utilize IVUS in the patient presented in this report because angiographic assessment revealed high diagnostic accuracy. We did not expect further information from additional imaging that might have changed clinical decision making. Without any randomized trials on treatment of coronary artery dissection, the literature consists of case reports and case series. Spontaneous resolution of the dissection has been reported in asymptomatic patients with hemodynamic stability and TIMI III coronary flow [19]. Coronary angioplasty with stent placement or coronary artery bypass graft should be indicated in case of persistent symptoms, hemodynamic instability and ST elevation. Current generation of drug-eluting stents has significantly improved the outcomes of percutaneous coronary intervention. Only recently, a BVS stent was implanted in a coronary dissection [20]. When coronary angioplasty is the choice, the American Heart Association guideline recommend [21] very careful consideration of the probability of long-term compliance before a drug-eluting stent is used in a patient with cocaine-associated myocardial infarction. To the best of our knowledge, no data are available regarding the use of BVS system in patients with cocaine-induced SCAD during ACS, but they would be expected to have the same advantages [22] as in patients who do not

use cocaine. These include restoration of vasomotion, reduction in late luminal enlargement and late or very late stent thrombosis, future coronary percutaneous or surgical revascularization. In our patient, a BVS stent implantation was opted for the type and site of coronary lesion and for the personal characteristic of the patient, concerning the age and the recent onset of cocaine use, thinking to have offered him the best and tailored strategy available today.

## References

1. Pepine CJ, Feldman RL, Conti CR (2014) Action of intracoronary nitroglycerin in refractory coronary artery spasm. *Circulation* 129: 1717-1719.
2. Maeder M, Ammann P, Angehrn W, Rickli H (2005) Idiopathic spontaneous coronary artery dissection: incidence, diagnosis and treatment. *Int J Cardiol* 101: 363-369.
3. Hamilos MI, Kochiadakis GE, Skolidis EI, Igoumenidis NE, Chrysostomakis SI, et al. (2003) Acute myocardial infarction in a patient with spontaneous coronary artery dissection. *Hellenic J Cardiol* 44: 348-351.
4. Koul AK, Hollander G, Moskovits N, Frankel R, Herrera L, et al. (2001) Coronary artery dissection during pregnancy and the postpartum period: two case reports and review of literature. *Cathet Cardiovasc Interv* 52: 88-94.
5. Suh SY, Kim JW, Choi CU (2007) Complete angiographic resolution of spontaneous coronary artery dissection associated with sleep deprivation. *Int J Cardiol* 119: e38-e39.
6. Ellis CY, Haywood GA, Monro JL (1994) Spontaneous coronary artery dissection in a young woman resulting from an intense gymnasium "work out". *Int J Cardiol* 47: 193-194.
7. Aldoboni AH, Hamza EA, Majdi K, Ngibzadhe M, Palasaidi F, et al. (2002) Spontaneous dissection of coronary artery treated by primary stenting as the first presentation of systemic lupus erythematosus. *J Invasive Cardiol* 14: 694-696.
8. Eltchaninoff H, Cribier A, Letac B (1997) Peripheral and coronary dissection in a young woman. A rare case of type IV Ehler-Danlos syndrome. *Arch Mal Coeur Vaiss* 90: 841-844.
9. Azam MN, Roberts DH, Logan WFWE (1995) Spontaneous coronary artery dissection associated with oral contraceptive use. *Int J Cardiol* 48: 195-198.
10. Ljsselmuiden A, Verheye S (2009) Cocaine-Induced coronary artery dissection. *JACC Cardiovasc Interv* 2: 1031.
11. Jaffe BD, Broderick TM, Leier CV (1994) Cocaine-induced coronary artery dissection. *N Engl J Med* 330: 510-511.
12. Lange RA, Cigarroa RG, Yancy CW Jr, Willard JE, Popma JJ, et al. (1989) Cocaine-induced coronary-artery vasoconstriction. *N Engl J Med* 321: 1557-1562.
13. Flores ED, Lange RA, Cigarroa RG, Hillis LD (1990) Effect of cocaine on coronary artery dimensions in atherosclerotic coronary artery disease: enhanced vasoconstriction at sites of significant stenoses. *J Am Coll Cardiol* 16: 74-79.
14. Mittleman MA, Mintzer D, Maclure M, Tofler GH, Sherwood JB, et al. (1999) Triggering of myocardial infarction by cocaine. *Circulation* 99: 2737-2741.
15. Wilbert-Lampen U, Seliger C, Zilker T, Arendt RM (1998) Cocaine increases the endothelial release of immunoreactive endothelin and its concentrations in human plasma and urine: reversal by incubation with sigma-receptor antagonists. *Circulation* 98: 385-390.
16. Mo W, Singh AK, Arruda JA, Dunea G (1998) Role of nitric oxide in cocaine-induced acute hypertension. *Am J Hypertens* 11: 708-714.
17. Kugelmass AD, Oda A, Monahan K, Cabral C, Ware JA (1993) Activation of platelets by cocaine. *Circulation* 88: 876-883.
18. Paulo M, Sandoval J, Lennie V, Dutary J, Medina M, et al. (2013) Combined use of OCT and IVUS in spontaneous coronary artery dissection. *JACC Cardiovasc Imaging* 6: 830-832.
19. Choi JW, Davidson CJ (2002) Spontaneous multivessel coronary artery dissection in a long-distance runner successfully treated with oral antiplatelet therapy. *J Invasive Cardiol* 14: 675-678.
20. Sengottuvelu G, Rajendran R (2014) Full polymer jacketing for long-segment spontaneous coronary artery dissection using bioresorbable vascular scaffolds. *JACC Cardiovasc Interv* 7: 820-821.
21. McCord J, Jneid H, Hollander JE, de Lemos JA, Cercek B, et al. (2008) Management of Cocaine-Associated Chest Pain and Myocardial Infarction: A Scientific Statement From the American Heart Association Acute Cardiac Care Committee of the Council on Clinical Cardiology. *Circulation* 117: 1897-1907.
22. Onuma Y, Serruys PW (2011) Bioresorbable scaffold. The advent of a new era in percutaneous coronary and peripheral revascularization? *Circulation* 123: 779-797.

**Copyright:** © 2014 Ceravolo R, et al. This is an open-access article distributed under the terms of the Creative Commons Attribution License, which permits unrestricted use, distribution, and reproduction in any medium, provided the original author and source are credited.

**Citation:** Ceravolo R, Vatrano M, Dattilo G, Ferraro A, Ciconte VA, et al. (2014) Spontaneous Coronary Artery Dissection and Implantation of Absorbable Bioresorbable Drug-Eluting Stent in Cocaine-Related Acute Coronary Syndrome. *J Cardiovasc Med Cardiol* 1(2): 030-032. DOI: 10.17352/2455-2976.000007