

## Tagesu Abdisa Serbessa\*

Jimma University, School of Veterinary Medicine,  
Jimma, Oromia, Ethiopia

**Received:** 14 May, 2018

**Accepted:** 13 August, 2018

**Published:** 14 August, 2018

**\*Corresponding author:** Tagesu Abdisa Serbessa,  
Jimma University, School of Veterinary Medicine,  
Jimma, Oromia, Ethiopia, Tel: +251933681407,  
E-mail: abdisatagesu@gmail.com

<https://www.peertechz.com>

## Research Article

# Skin scraping

Skin scrapings are part of the basic database for all skin diseases. There are two types of skin scrapings, superficial and deep. Superficial scrapings do not cause capillary bleeding and provide information from the surface of the epidermis. Deep skin scrapings collect material from within the hair follicle; capillary bleeding indicates that the sampling was deep enough. Skin scrapings are used primarily to determine the presence or absence of mites. Skin scrapings are best performed using a skin-scraping spatula, which is a thin metal weighing spatula commonly found in pharmacy or chemical supply catalogs. These spatulas are reusable and do not cause injury [1]. Skin scrapings help diagnose fungal infections and scabies. For fungal infection, scale is taken from the border of the lesion and placed onto a microscope slide. Then a drop of 10 to 20% potassium hydroxide is added. Hyphae, budding yeast, or both confirm the diagnosis of tinea or candidiasis. For scabiesscrapings are taken from suspected burrows and placed directly under a coverslip with mineral oil; findings of mites, feces, or eggs confirm the diagnosis [1,2]. The skin scraping can be classified into two, superficial and deep scraping.

### Superficial skin scraping

Superficial scraping used to identify surface mites and multiple scrapings should be taken to increase the likelihood of ectoparasites (Cheyletiella, Sarcoptes, Psoroptes, Otodectes, and Demodex mites, fleas and lice) detection [2,3].

The procedure of superficial scraping [3-6]:

- Remove the hair coat in the area by gentle clipping and after clipping the hairs the area has to be sterilized with antiseptics (chlorhexidine, soap)
- A few drops of liquid paraffin can be applied and spread over the skin scraping site, then scraping with a blunt scalpel blade

- Holding the blade perpendicular to the skin or slightly deviated away from the direction of scraping, the blade is gently passed over large areas of the skin in a sweeping pattern.
- Don't be apply 10% KOH directly to skin
- Take the scraped hair and skin content into petri dish
- Emulsion of scant material( superficial epidermis) is spread over a microscope slide or petri dish
- Add 2 -3 drops of 10% KOH into scraped sample and mix it
- It is warmed for about 3 minutes
- Covered with a cover slide and the slide is examine under microscope at 10x low power, to see adult, larvae, nymph and egg of parasite

### Deep skin scraping

Deep skin scraping is important in the diagnosis of burrowing and deep follicular mites such as *Sarcoptes scabiei* and *Demodex* sp. The technique is repeated until capillary blood oozes out and multiple sites should be scraped to maximize detection of ectoparasites.

Procedure [2,3,7]:

- The hair should be clipped with scalpel blade. Holding the blade perpendicular to skin and blade is gently passed over a small area of lesional skin in a sweeping pattern. The skin should be pinched firmly between the thumb and forefinger to help extrude the parasite from deeper epidermal layer.
- Place the scalpel blade with material removed into petri dish or other container
- The collected material is mounted onto glass slide in liquid paraffin or potassium hydroxide.
- Cover aslide should be applied into sample collected on slide and examine it under low power objective of microscope

- Scan the parasite entire of slide and mite structure will observe as figure 1.

### Examination of fungus from scraping

Fungal examination of skin scrapings is indicated when fungal infection of skin is suspected. The site of collection of scrapings should be the most active lesion at skin. Since some fungal infections spread towards the periphery, it is advisable to collect the scrapings from centre as well as from periphery of the lesion. When dermatophytes fungi affect skin and hair of the animal it will produce white greyish circular lesion accompanied with crust, scale, hyperkeratosis and alopecia. Those lesions normally found in the face, neck, chest, leg and body of the animal [8]. Before collection of the scrapings, skin is swabbed with 95% alcohol or spirit to remove any saprophytic organism. The scalpel should be moistened with mineral oil and the skin scrapped deeply to include hairs.

The skin scrapings are collected in sterilized petridishes containing 10% potassium hydroxide or sodium hydroxide. Fungi are usually isolated on Sabouraud dextrose agar which inhibits growth of most bacteria. The addition of chloramphenicol and cycloheximide increases sensitivity by inhibiting some of the fast growing contaminating bacteria and other microorganism [10]. Hair plucking can be collected and inoculated using sterile forceps into one of two media like sabouraud's agar or dermatophyte test medium. The culture should be kept at room temperature for 7-10 days and checked for appearance of colony of white colony and red coloration of the medium, which indicates presence of dermatophytes. However, if no growth after 3 weeks, the sample can be negative of ring worm [3].

Sabouraud's dextrose agar (SDA) and isolated selective media containing cycloheximide, penicillin and streptomycin were used in most diagnostic laboratories until point-of-care fungal culture medium was developed. In the late 1960s Dermatophyte Test Medium (DTM) was developed for field evaluation by paramedical personnel for skin infections in military forces operating in the tropics [11]. Dermatophyte Test Medium is a nutrient growth medium with antibiotics to suppress bacterial and contaminant fungal overgrowth and a colour indicator to aid in the early recognition of possible dermatophyte species. The colour change in the medium from yellow to red is the result of a pH change triggered by fungal growth. The first published article concluded that colour change alone was diagnostic of a dermatophyte, but numerous studies shortly thereafter documented a wide range of contaminants that also cause a red colour change in the medium [12,13].

The Wood's lamp has UV light, which is directed on the intact skin or on the scrapings collected in petridishes (Figure 2). If the fungus *Microsporum* is present, it gives yellow-green fluorescence while no fluorescence is observed in negative or trichophyton fungal infection of skin. The Wood's lamp is a point-of-care diagnostic tool, with which a test can be performed in clinic. It is an ultraviolet lamp that was invented in 1903 by Robert W. Wood as a light filter used in communications during World War I.

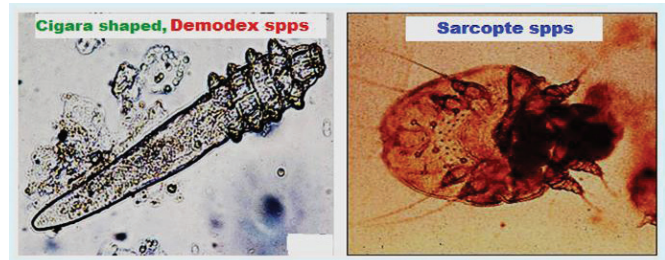


Figure 1: The structure of mite which obtained from scraping of skin (<http://orsofia.com/30206/bogdan-the-mengy-pup>).



Figure 2: Wood's lamp for diagnosis of fungal disease in domestic animals.

The original glass filter material has been replaced by newer materials (e.g. barium-sodium-silicate glass incorporating 9% nickel oxide) that coat the inside of glass tubes. The Wood's lamp glass is deep violet blue and is opaque to all visible light rays except the longest red and shortest violet wavelengths. It is transparent in the violet/ultraviolet band between 320 and 400 nm with a peak at 365 nm and a broad range of infrared and the longest, least visible red wavelengths [14]. Fluorescence occurs when light of shorter wavelengths initially emitted by the lamp, is absorbed and radiation of longer wavelengths is emitted [14]. Thus, it excludes most of the burning and tanning shorter rays (<320 nm) and the visible rays longer than 400 nm). A Wood's lamp is often mistakenly referred to as a "black light" but these are distinctly different things [14].

A black light is composed of a clear glass that filters medium- and short-wave ultraviolet light (UV) and emits a large amount of blue visible light along with long-wave UV light. An example of a black light is the black light bulbs in bug catchers. It is hard to see fluorescence due to the large amount of visible light. Many microbial organisms produce phosphors as a result of their growth on skin and/or hairs and this can aid in detection and/or confirmation of infection. With the exception of *T. schoenleinii*, dermatophytes that produce fluorescence are members of the *Microsporum* genus. The primary dermatophyte of veterinary importance that produces fluorescence is *M. canis*. Clinical reports of *M. gypseum* or *M. persicolor* dermatophytosis in dogs and cats note a lack of fluorescence on infected hairs [15-18].

### References

1. Kahn CM (2010): Merck Veterinary Manual. 10th edn. Whitehouse Station, Merck, NJ, USA.
2. Bosch X, Poch E, Grau JM (2009). Rhabdomyolysis and acute kidney injury. *N Engl J Med*; 361(1):62-72.
3. Barger, A. M., & MacNeill, A. L. (Eds.). (2015). *Clinical Pathology and Laboratory Techniques for Veterinary Technicians*. John Wiley & Sons.

4. John Wiley & Sons. Orpet, H., & Welsh, P. (2010). Handbook of veterinary nursing. John Wiley & Sons
5. Obtaining a skin scraping. Website at: <http://veterinarymedicine.dvm360.com/obtaining-skin-scraping?pageID=2>
6. Skin scrapings and mange mites collection techniques. Website at: [http://files.upei.ca/avc/diagnosticservices/AVCDS\\_SkinScrapings.pdf](http://files.upei.ca/avc/diagnosticservices/AVCDS_SkinScrapings.pdf)
7. Veterinary clinical biochemistry and laboratory diagnosis. Website at: <http://www.elearnvet.net/moodle/mod/resource/view.php?id=19437>
8. Mecklenburg, L., Linek, M., & Tobin, D. J. (Eds.). (2009). Hair loss disorders in domestic animals. John Wiley & Sons.
9. Sharma, D. K., Joshi, G., Singathia, R., Lakhotia, L. R. (2010). Fungal Infections In Cattle In A Gaushala At Jaipur. Haryana Vet. 49:62-63.
10. Quinn, P. J., Markey, B. K., Leonard, F. C., Hartigan, P., Fanning, S., & FitzPatrick, E. S. (2011). Veterinary microbiology and microbial disease
11. Diagnostic testing dermatology. Website at: [https://sonopath.com/sites/default/files/downloads/article\\_casey\\_DERMATOLOGY\\_Diagnostic\\_Tests.pdf](https://sonopath.com/sites/default/files/downloads/article_casey_DERMATOLOGY_Diagnostic_Tests.pdf)
12. Sinski JT, Swanson JR, Kelley LM (1972). Dermatophyte test medium: clinical and quantitative appraisal. J Invest Dermatol 1972; 58: 405–411
13. Taplin D, Zaias N, Rebell G (1969). Isolation and recognition of dermatophytes on a new medium (DTM). Arch Dermatol; 99: 203–209.
14. Wilson, D. (2010). Clinical Veterinary Advisor-E-Book: The Horse. Elsevier Health Sciences
15. Asawanonda P, Taylor CR. (1999). Wood's light in dermatology. Int J Dermatol; 38: 801–807.
16. Kano R, Yasuda K, Nakamura Y. (2001). Microsporium gypseum isolated from a feline case of dermatophytosis. Mycoses; 44: 338–341.
17. Muller A, Guaguère E, Degorce-Rubiales F (2011). Dermatophytosis due to Microsporium persicolor: a retrospective study of 16 cases. Can Vet J ; 52: 385–388
18. Nardoni S, Mugnaini L, Papini R (2013). Canine and feline dermatophytosis due to Microsporium gypseum: a retrospective study of clinical data and therapy outcome with griseofulvin. J Mycol Med; 23: 164–167.